Clinical Journal of Plastic and Reconstructive Surgery
An official Journal of KGMU Plastic Surgery Education Foundation

CASE REPORT
Volume 4 | Issue 1 | January-June 2026
Published on: 9th August, 2026
www.cjprs.in

Solitary Extra Digital Glomangioma at the Infra-clavicular Region: A Rare Case Report

Nanthini Dhevi[1], **Fahima Hussaina**[2], **Jaishree Tamilmani**[3]

Keywords:
Glomangioma, anaesthesia, glomus body

doi: 10.61081/cjprs/4v1i107

ABSTRACT

Glomangioma is an uncommon benign vascular neoplasm of the glomus body, typically encountered in the digits. Extradigital presentation is rare and may lead to delayed or missed diagnosis. We report a case of a 31-year-old male who presented with a two-year history of pain in the left infraclavicular region, worsened by palpation, without any externally visible swelling. MRI demonstrated a soft tissue lesion in an unusual deep location beneath the subscapularis and pectoral muscles. The lesion was managed by complete excision under general anaesthesia. Gross examination revealed an oval purplish mass measuring 2.5 × 1.5 × 1.5 cm, and histopathology confirmed the diagnosis of glomangioma. Postoperatively, the patient had complete relief of symptoms. This case underscores the need to include glomangioma in the differential diagnosis of painful extradigital lesions and highlights surgical excision as the definitive treatment.

Clinical Journal of Plastic and Reconstructive Surgery, 2026;4(1).

INTRODUCTION

Glomangiomas are a vascular variant of glomus tumours, which are rare benign neoplasms arising from the glomus body—a thermoregulatory neuromyoarterial plexus composed of an afferent arteriole, anastomotic vessel and collecting venule located within the dermis. Glomus tumours originate from modified smooth muscle cells of the glomus body, which functions in temperature regulation. These tumours account for less than 2% of all soft tissue tumors.[1]

Glomangiomas, also known as glomuvenous malformations, are characterized histologically by abnormal, dilated, thin-walled vascular channels lined with multiple layers of glomus cells.[2] They represent multiple glomus tumours and are a less common subtype, accounting for less than 10% of all glomus tumour cases.[1] Unlike classic solitary glomus tumours that typically present between ages 20–40 with excruciating pain and are found in the nail bed, glomangiomas are more common in males, are located on the trunk and extremities (particularly the forearm), and are often asymptomatic or less painful.[3]

Familial glomangiomas are inherited in an autosomal dominant pattern and are caused by truncating mutations in the glomulin (GLMN) gene on chromosome 1p21-22.[4] Multiple glomus tumours develop 11–15-years earlier than solitary lesions, with approximately one-third of cases occurring in individuals younger than 20-years of age.[1] The development of these lesions follows Knudson's "two-hit" hypothesis, with a somatic mutation required in addition to the inherited germline mutation.[5] Surgical excision remains the preferred treatment for glomus tumors Malignant transformation (glomangiosarcoma) is extremely rare.[3]

[1]*Department of Plastic Surgery, Sir Ivan Stedeford hospital, Ambattur, Chennai, Tamil Nadu, India*
[2] *Department of General Surgery, Sir Ivan Stedeford Hospital, Ambattur, Chennai, Tamil Nadu, India*
[3]*Consultant Pathologist, Sir Ivan Stedeford Hospital, Ambattur, Chennai, Tamil Nadu, India*
***Correspondence:** *Nanthini Dhevi (drnanthu@gmail.com)*
Conflicts of interest: *None declared.*
Funding: *None declared.*
How to cite: *Dhevi N, Hussaina F, Tamilmani J. Solitary Extra Digital Glomangioma at the Infra-clavicular Region: A Rare Case Report. Clinical Journal of Plastic and Reconstructive Surgery. 2026;4(1):37–40*

©The Author(s). 2026 Open Access This article is distributed under the terms of the Creative Commons Attribution-NonCommercial-ShareAlike 4.0 International (CC BY-NC-SA 4.0) (https://creativecommons.org/licenses/by-nc-sa/4.0/)

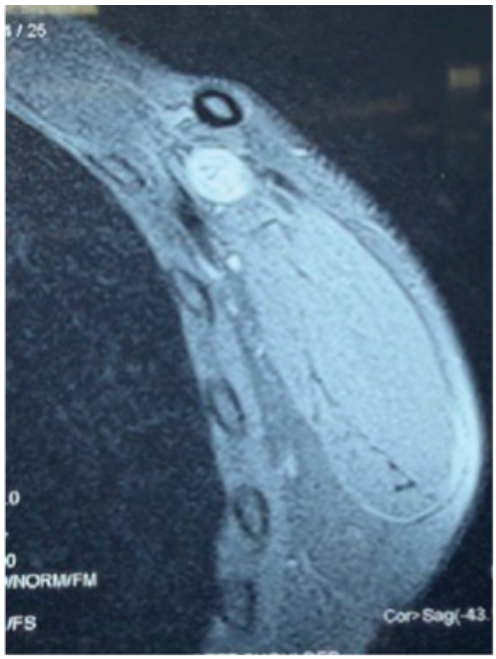

Figure 1: MRI image showing the deep solitary glomangioma.

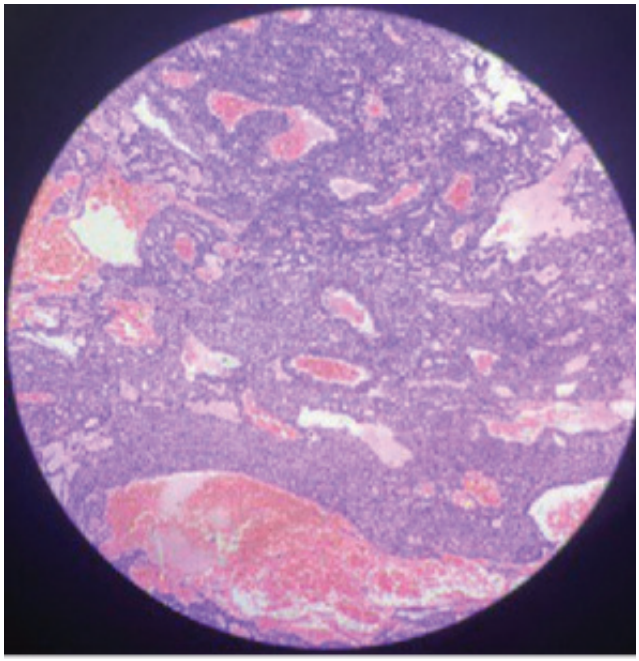

Figure 3: Glomangioma –10 x collars of round glomus cells surrounding dilated caernous spaces.

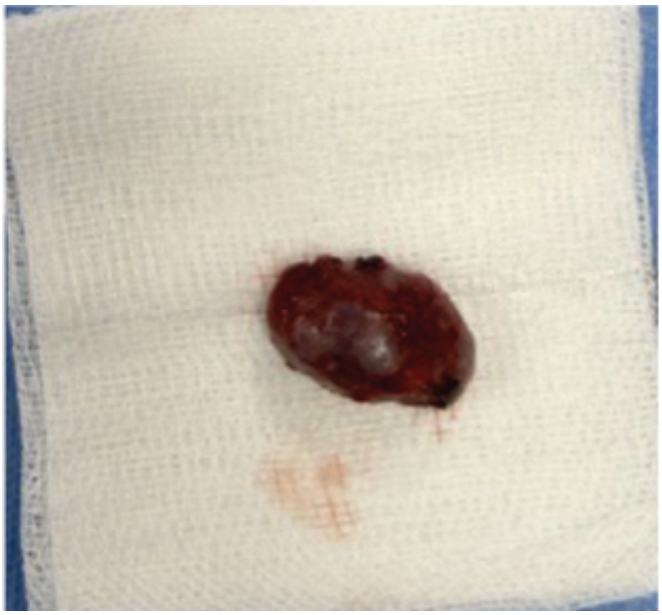

Figure 2: Gross excised specimen - 2.5 x 1.5 x 1.5 cm.

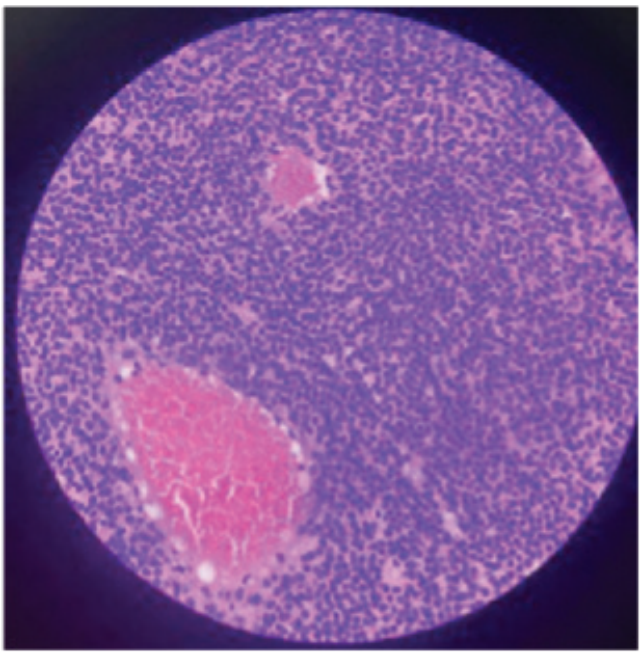

Figure 4:Glomangioma, 40 x High power view shows that the cells are uniform with indistinct borders, eosinophilic cytoplasm, round nuclei, and bland chromatin.

CASE REPORT

A 31-year-old male was referred to Department of Plastic Surgery, Sir Ivan Stedeford hospital, Ambattur, Chennai, Tamil Nadu with a diagnosis of soft tissue swelling in left infraclavicular region for further management. Patients started to have pain in the left infra clavicular region 2-years back, and pain slowly increased in intensity with aggravation on palpation without any externally visible swelling. On evaluation elsewhere with an MRI scan, patients were found to have a soft tissue swelling in the region. Patient did not have swelling elsewhere in the body and had no family history.

As per radiological evidence, the swelling was lying beneath subscapularis and behind the pectoral muscles with lateral border containing deltoid and cephalic veins. considering this location, an excision biopsy of the lesion was planned under General anaesthesia. Swelling was excised in toto, it was oval purplish measuring 2.5 x 1.5 x 1.5 cm with a firm consistency. The excised specimen was sent for histopathological evaluation. Ultimately, the diagnosis of Glomangioma was established. Post-operatively patient had complete relief from the pain which was his presenting symptoms.

DISCUSSION

Glomus tumours are benign vascular neoplasms that are typically easy to diagnose in the digits but may be diagnostically challenging when they occur at extradigital sites. Extra digital frequency varies from 11% to 65%.[7] Complete surgical excision remains the definitive treatment and is usually curative for solitary lesions.[6] Extradigital tumours have been described in a wide range of sites, including the foot, forearm,[10] lower lip,[11] mediastinum,[12] shoulder, upper back,[13] thigh, calf, ankle, buttock, trunk, abdomen, arm, lung, stomach, and vertebrae.[9]

Clinically, these lesions are characterized by disproportionate pain that radiates away from the tumour, tenderness, and cold sensitivity,[14] with symptoms linked to substance P–positive nerve fibers[15] and thermosensitive TRP (Transient Receptor Potential) channels.[16] Although recurrence may occur, it is usually related to incomplete excision which range from 12 to 33%.[17,18] Malignant glomus tumours are rare, and suspicious features include deep location, size exceeding 2 cm, a typical mitoses, higher nuclear grade, and increased mitotic activity , ≥5 mitotic figures per 50 high-power field.[9]

CONCLUSION

We have reported a case of Glomangioma found at the infraclavicular region. When glomus tumours occur in unusual sites or with atypical symptoms, diagnosis can become challenging. So, it is important to consider Glomus tumours as differential diagnosis when purplish painful lesions with or without temperature sensitivity present themselves.

Funding: No funds, grants, or other support was received **Conflict of interest:** The authors have no relevant financial or non-financial interests to disclose.

Ethics approval: As per policy of the research ethics committee of the institute, prior approval for a case report is not required.

Consent to participate:

Written informed consent for participation was obtained from the patient.

Consent for publication:

Written informed consent for publication of patient's clinical details and/or clinical images was obtained from the patient.

Availability of Data and Material:

clinical photographs and case record sheets are available.

REFERENCES

1. Hartnick CJ, Haver K, Pilch BZ, Harris NH. Case 10-2008: A 10-Year-Old Girl with Dyspnea and Noisy Respirations. N Engl J Med. 2008;358(15):1529-1539. doi:10.1056/NEJMcp0800629[journals.sagepub]
2. Bistazzoni S, Polosa M, Bellocchi SD Unusual Location of Glomus Tumors Case Rep Imag Surg.2020;3:1000144. doi:10.15761/CRIS.1000144[nih]
3. Figueroa-Basurto CI, Castro DA, Hernández MLC, et al. Glomus Cell Tumors: Demographic and ClinicalCharacteristics. Cureus. 2025;17(5):e84615. doi:10.7759/cureus.84615[radiopaedia]
4. LimasC,-F. Mutations in a novel factor, glomulin, are responsible for glomuvenous malformations ("glomangiomas"). Am J Hum Genet. 2002;70(4):866-874. doi:10.1086/339494
5. Vaultier-Grymonprez M, et al. Four common glomulin mutations cause two thirds of glomuvenousmalformations ("familial glomangiomas"): evidence for a founder effect. J Med Genet. 2005;42(2):e13.doi:10.1136/jmg.2004.024174
6. Tomak Y, Dabak N and Ozcan H: Extradigital glomus tumor of the triceps tendon as a cause of elbow pain: a case report. J Shoulder Elbow Surg. 12:401–402. 2003.
7. BeatonLIandDavisL: Glomus tumor: report of three cases and analysis of 271 recorded cases. Q Bull Northwest Univ Med School. 15:245–273. 1941.
8. Lee DW, Yang JH, Chang S, Won CH, Lee MW, Choi JH and Moon KC: Clinical and pathological characteristics of extradigital and digital glomus tumors: a retrospective comparative study. J Eur Acad Dermatol Venereol. 25:1392–1397. 2011.

9. Folpe, Andrew L. M.D.; Fanburg–Smith, Julie C. M.D.; Miettinen, Markku M.D.; Weiss, Sharon W. M.D.. Atypical and Malignant Glomus Tumors: Analysis of 52 Cases, With a Proposal for the Reclassification of Glomus Tumors. The American Journal of Surgical Pathology 25(1): p 1-12, January 2001.
10. CalonjeE: Vascular tumors: tumors and tumor-like conditions of blood vessels and lymphatics. Lever's Histopathology of the Skin. 10th edition. Lippincott Williams and Wilkins; Philadelphia, PA: pp.
11. 1047–1049. 2009
12. Lanza A, MoscarielloA, VillaniR and ColellaG: Glomus tumor of the lower lip. A case report. Minerva Stomatol. 54:687–690. 2005.
13. Gaertner EM, Steinberg DM, Huber M, Hayashi T, Tsuda N, Askin FB, et al: Pulmonary and mediastinal glomus tumors - Report of five cases including a pulmonary glomangiosarcoma: a clinicopathologic study with literature review. Am J Surg Pathol. 24:1105–1114. 2000.
14. Takei TR and Nalebuff EA: Extradigital glomus tumour. J Hand Surg Br. 20:409–412. 1995.
15. Weiss SW and GoldblumJR: Perivascular tumors. Enzinger and Weiss's Soft tissue tumors. 5th edition. Mosby; Maryland Heights, MO: pp. 751–756. 2007.
16. Kishimoto S, NagataniH, MiyashitaA and KobayashiK: Immunohistochemical demonstration of substance P-containing nerve fibres in glomus tumors. Br J Dermatol. 113:213–218. 1985.
17. McKemyDD: How cold is it? TRPM8 and TRPA1 in the molecular logic of cold sensation. Mole Pain. 1:16 2005.
18. Rettig AC and Strickland JW: Glomus tumor of the digits. J Hand Surg Am. 2:261–5. 1977.
19. Strahan J and Bailie HW: Glomus tumour. A review of 15 clinical cases. Br J Surg. 59:91–3. 1972.