Clinical Journal of Plastic and Reconstructive Surgery
An official Journal of KGMU Plastic Surgery Education Foundation

CASE REPORT
Volume 4 | Issue 1 | January-June 2026
Published on: 9th August, 2026
www.cjprs.in

Surgical Correction of Rare Deformity: Congenital Double Upper Lip

Pavneet Kaur Soni, Rajesh Kumar Thakur, Bipin Kumar Yadav, Prerna Kataria, Pooja Yadav

Keywords: *Congenital double lip, Developmental anomaly, Esthetic surgery, Periodontology, Upper lip*

doi: 10.61081/cjprs/4v1i108

ABSTRACT

Congenital double lip is a rare developmental anomaly characterized by redundant mucosal tissue, usually affecting the upper lip and becoming more prominent during smiling. A 36-year-old male presented with an unaesthetic smile and recurrent lip biting. Clinical examination revealed a congenital double upper lip without systemic features of Ascher syndrome. Surgical excision of the redundant tissue was performed under local anesthesia. Healing was uneventful, and at one month the patient demonstrated excellent esthetic improvement and complete resolution of functional complaints.

*Clinical Journal of Plastic and Reconstructive Surgery, 2026;*4(1).

INTRODUCTION

Double lip is an uncommon developmental anomaly caused by persistence of the horizontal sulcus between the pars glabrosa and pars villosa during embryogenesis. The lesion usually becomes apparent during smiling because contraction of the orbicularis oris muscle accentuates the redundant mucosal fold.[1,2] The condition may be congenital or acquired and can occur alone or as part of Ascher syndrome. Surgical excision is the treatment of choice when esthetics or function is affected.

CASE PRESENTATION

A 36-year-old male reported with the chief complaint of an unpleasant smile and occasional lip biting during mastication. Medical and family histories were non-contributors. Intraoral examination showed moderate plaque and calculus deposits and a redundant fold of upper labial mucosa that became prominent during smiling, producing a characteristic cupid's bow appearance. No blepharochalasis or thyroid enlargement was present.

PROCEDURE

Under local anesthesia (2% lignocaine with 1:100,000 adrenaline), the redundant upper labial mucosa was outlined using a sterile marking pen. An elliptical incision extending bilaterally along the redundant pars villosa was placed, preserving the labial frenum. The hyperplastic mucosal and submucosal tissue was carefully excised while avoiding injury to the orbicularis oris muscle. Hemostasis was achieved, and the wound margins were approximated with interrupted 4-0 black silk sutures, producing a symmetrical upper lip contour. Post-operative instructions included a soft diet, maintenance of oral hygiene, chlorhexidine mouth rinse, analgesics/antibiotics as indicated, and review after one week for suture removal.

RESULT

Immediate postoperative healing was uneventful. At one week, the surgical site showed satisfactory healing without infection or wound dehiscence.

Department of Periodontology, Faculty of Dental Sciences, Uttar Pradesh University of Medical Sciences, Saifai, Etawah, Uttar Pradesh, India

***Correspondence:** *Pavneet Kaur Soni (pavneet891@gmail.com)*

Conflicts of interest: *None declared.*

Funding: *None declared.*

How to cite: *Soni PK, Thakur RK, Yadav BK, Kataria P, Yadav P. Surgical Correction of Rare Deformity: Congenital Double Upper Lip. Clinical Journal of Plastic and Reconstructive Surgery. 2026;4(1):41–43*

©The Author(s). 2026 Open Access This article is distributed under the terms of the Creative Commons Attribution-NonCommercial-ShareAlike 4.0 International (CC BY-NC-SA 4.0) (https://creativecommons.org/licenses/by-nc-sa/4.0/)



Figure 1: Pre-operative frontal view showing a congenital double upper lip while smiling.



Figure 2: Surgical markings outlining the redundant mucosal tissue.



Figure 3: Elliptical excision of redundant mucosa with preservation of the labial frenum.



Figure 4: Immediate postoperative appearance after primary closure with interrupted 4-0 silk sutures.



Figure 5: 1-week postoperative healing following suture placement.



Figure 6: 3 months postoperative photo.

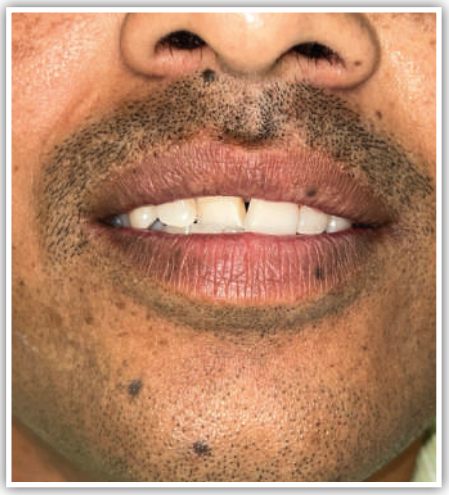

Figure 7: 6-months postoperative photo



Figure 8: One-year postoperative follow-up demonstrating excellent esthetics and absence of recurrence.

At one month, the upper lip contour was markedly improved with resolution of the redundant fold. Three- and six-month follow-up demonstrated stable esthetic improvement without scar contracture or functional impairment. At one-year follow-up, no recurrence of the deformity was observed. The patient reported complete resolution of lip biting during mastication, improved smile esthetics, and high overall satisfaction.

DISCUSSION

Congenital double lip is an uncommon developmental anomaly resulting from persistence and hypertrophy of the pars villosa of the lip. It usually becomes evident during smiling due to contraction of the orbicularis oris muscle.[1,2] Surgical excision remains the treatment of choice when esthetic concerns or functional problems such as lip biting or speech interference are present. Although congenital double lip may occur as an isolated finding, it should always be evaluated for association with Ascher syndrome, which classically includes double lip, blepharochalasis and nontoxic thyroid enlargement. In the present case, no clinical features suggestive of Ascher syndrome were observed.[3,5] This case was managed using a conservative transverse elliptical excision while preserving the labial frenum, providing excellent symmetry and minimizing postoperative scarring. The sequential follow-up

photographs demonstrated progressive maturation of the surgical site with excellent contour and no evidence of recurrence for up to one year. The favorable long-term outcome emphasizes that meticulous tissue handling, preservation of muscular integrity, and tension-free primary closure are key determinants of successful management. These findings corroborate previous reports indicating that recurrence following complete excision is uncommon, and patient satisfaction is generally high.[2,4]

CONCLUSION

Congenital double upper lip is a rare but correctable developmental anomaly. Early recognition and appropriate surgical management provide predictable esthetic and functional outcomes with high patient satisfaction.

REFERENCES

1. Costa-Hanemann JA, Tostes-Oliveira D, Fernandes-Gomes M, et al. Congenital double lip associated to hemangiomas: report of a case. *Med Oral Patol Oral Cir Bucal*. 2004;9:155-158.
2. Srivastava A, Parihar A, Soni R, Shashikanth MC, Chaturvedi TP. Surgical Management of a Rare Case of Congenital Double Upper Lip. *Case Reports in Medicine*. 2011.
3. Ariyawardana A. Congenital double upper lip: review of literature and report of a case. *J Investig Clin Dent*. 2011;2(3):212-215.
4. Congenital double upper lip: A case report and review of the literature. PMC
5. Barnett ML, Bosshardt LL, Morgan AF. Double lip and double lip with Ascher's syndrome. *Oral Surgery, Oral Medicine, Oral Pathology*. 1972;34:727-733.