

presentation is as multiple disseminated lesions in children and adolescents. This variant is more common in males and lesions are painless. Some of these cases are familial with autosomal dominant inheritance.

In the third variant, lesions are in groups and painful. This variant is also non-hereditary.⁷

Classically glomus tumours are benign but extremely rare instances of malignant transformation are described. The malignant version is locally infiltrative but metastasis has been documented.

PATIENTS AND METHODS

We operated 34 Nail beds for excision of glomus tumour (32 primary and 2 recurrences) in 29 patients between May 2013 and April 2017. All of our cases were diagnosed by Dermatologist (19 patients) and Neurologist (10 patients). On confirmation of the diagnosis or on a high degree of suspicion these patients were referred to the Plastic Surgery department for surgical intervention.

The diagnosis was made based on history, examination and imaging investigations. The pain of the subungual glomus tumour is paroxysmal, severe, originating from the affected nail and radiating proximally into the limb. Pain is triggered by pressure or temperature change.

Detailed examination of the involved nail was done under examination light using 2X magnification lens. A localised area of bluish or purple discolouration of nail with or without curvature changes or deformation of nail is seen in the case of a subungual glomus tumour.

Love's test (severe localised pain on the application of pressure on the suspected area with a pointed object like a pencil tip or pin head), *Hildreth sign* (reduction of pain and tenderness by inducing transient ischemia with tourniquet) and *Ice cube test* (pain on the application of ice on effected area) help establish clinical diagnosis.⁸⁻¹²

Radiographs of an affected finger in antero-posterior and lateral views were done in all patients. With small lesion, no radiological changes are seen but in the case of the large lesion, characteristic erosion of terminal phalanx is evident.

High-resolution ultrasonography was also ordered in all cases. MRI was done in all cases except in those

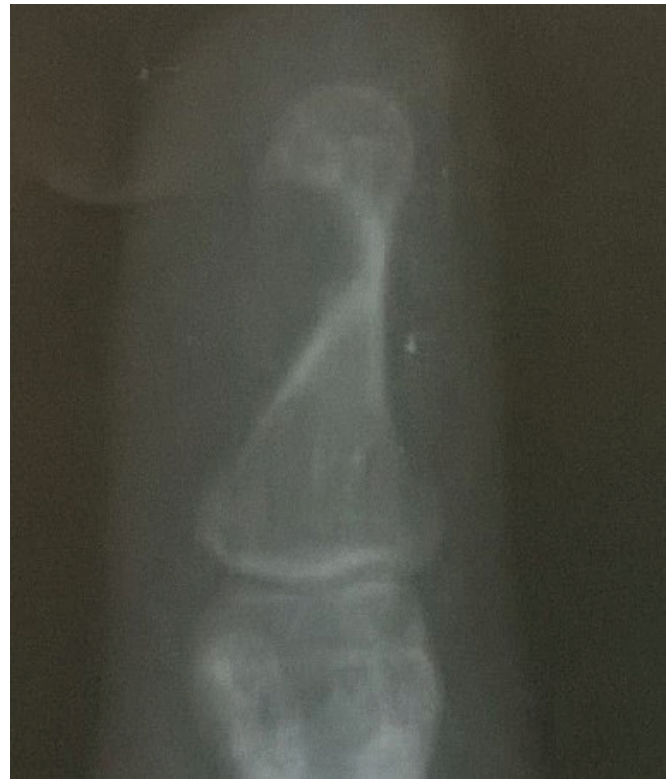

Figure 1: Erosion of distal phalanx seen on plain radiograph

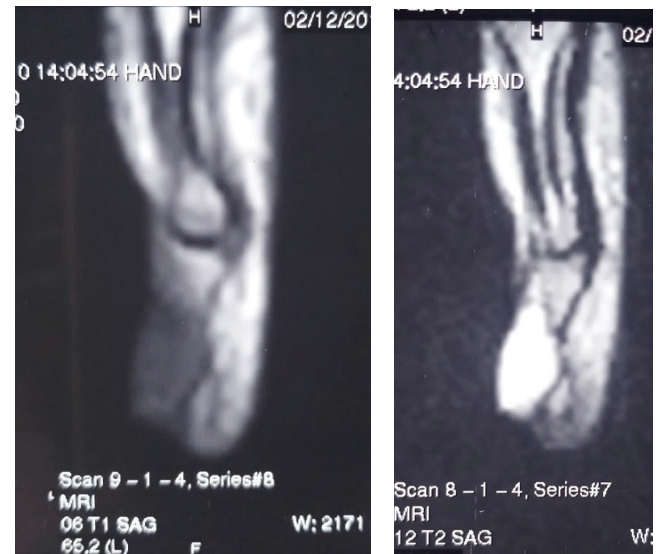


Figure 2: Hypointense on T1 and hyperintense on T2 image

where bony erosion of distal phalanx was evident on plain radiograph.

All the affected digits were explored under the ring block. The surgical glove finger was used as a tourniquet. 4.5X magnification with loupes was used. The nail plate was removed to expose the underlying nail bed. The tumour was visible through the nail bed (Figure 3).

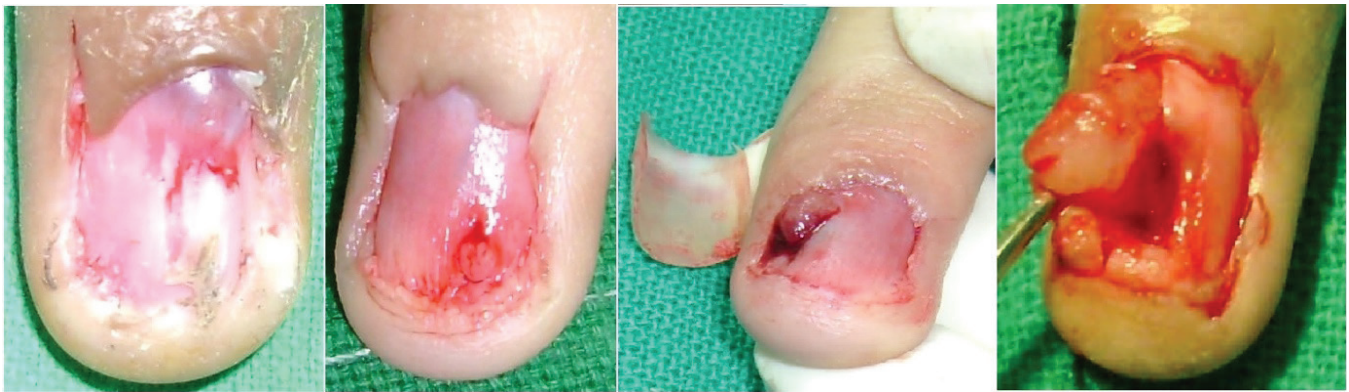

Figure 3: Tumour visible through nailbed. Approach via a longitudinal incision in nail bed. Note variation in size and site of lesions

An incision was given in nail bed overlying the tumour using a number 11 surgical blade. Tumour popped up on incising the nail bed and it was removed effortlessly by scooping it with the tip of a haemostat or small-size curette (Figure 3).

Confirmation of complete clearance was done by careful examination and then the field was irrigated with a strong jet of normal saline pushed with 10 mL syringe fitted with the hub of broken 22G needle. Nail bed was sutured with 5-0 chromic catgut. One or two holes were made in nail plate with 18G hypodermic needle. Then nail was replaced back in position and anchored to the tip of the finger with chromic catgut suture. Simple dressings were done. Repositioned nail helped preserve the nail fold and acted as a splint to the repaired nail bed.¹³ During subsequent dressings minimal pain was experienced by the patient as nail bed was protected by nails.

OBSERVATIONS AND DISCUSSION

In our series 24 (82.7%) patients were females. Our youngest patient was 19 years old and the oldest one was 55 years. The most common age group was of 31 to 40 years, followed by 41 to 50 years (Table 1).

Eighteen (62%) patients had lesions in the right hand and 11(37.9%) in left hand. Two patients had

synchronous lesions in adjacent fingers of same hand. One had three and the other two lesions in fingers of the same hand. The incidence of synchronous lesions in adjacent digits in this study (6.8%) is comparable to other studies.⁶

Severe paroxysmal pain originating from the affected nail and radiating proximally into the limb was chief complaint of 27 patients. Pain was triggered by pressure or temperature change. These patients were afraid of using the involved hand because of the fear of triggering the pain. Out of these 5 patients were protecting their involved digits with a protective dressing or handkerchief. Two of our patients consulted primarily for the deformity of nail. But when asked about pain, they gave history of occasional paroxysmal pain in finger. On inspection of involved nails, we found wide range of nail deformities (Figure 4).

In our series ten nails appeared normal on casual inspection but close examination revealed faint area of purple or cyanotic discolouration. Curvature changes of nail were appreciated in 14 nails. Nails were grossly deformed in 8 fingers (Table 2).

Love’s test and Hildreth’s test were done in all patients. Love’s test was positive in all cases. Hildreth’s test was positive in 21 (62%) cases but was equivocal in rest.

Table 1: Distribution of patients according to age

AGE (Years)	NUMBER OF PATIENTS
10–20	2
21–30	3
31–40	12
41–50	10
51–60	2

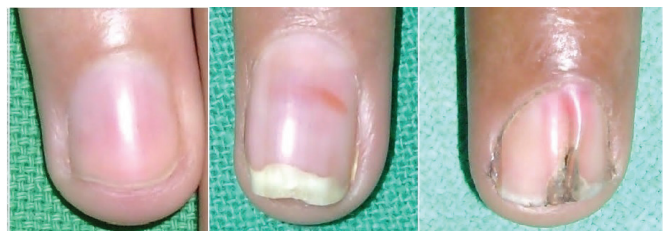

Figure 4: Variable degrees of Nail deformities.

Table 2: Findings on inspection of nails in 32 Primary lesions.

S. No	Findings on Inspection of Nail	Number of Nails
1	Normal looking Nails on casual examination	10
	A. Only blue/ purple discoloured area seen on careful examination	
2	B. Curvature changes in nail along with discolouration	14
	Deformed Nail	8

Ice cube test was performed in 15 cases only and it was found positive in all.

Bony erosion of distal phalanx was seen on radiography in 8 (25%) digits. All of these 8 digits had significant nail deformity and harboured large tumour. Incidence of bony erosion in subungual glomus tumours in various studies ranges from 22 to 50%.^{5,8}

Ultrasonography done by a dedicated radiologist can localise subungual glomus tumour.¹⁴ Ultrasonography was done in all patients with 10 MHz probe. Subungual glomus tumour appears as a hypoechogenic mass lying between nail plate and distal phalanx. Lesion shows intense vascularity. Ultrasonography is helpful in localisation and detecting the consistency and size of lesions. Limitations are dependence on the operator’s skills and difficulty in detecting small and flat lesions. In our series radiologist were able to detect lesions in 18(56.2%) digits.

On MRI glomus tumour appears as a well-defined hypointense lesion on T1 image and well delineated hyperintense mass on the T2-weighted image.¹⁵ Important differential diagnoses on MRI are neuroma, melanoma, foreign body, hemangioma and pigmented naevus. Enhancement of T1 image after injection of Gadolinium helps differentiate from mucoid cyst and epidermal inclusion cyst.

Table 3: Results of various imaging techniques in our study.

Investigation	Number of Digits Investigated	Number of Digits with Supportive Findings
Radiography (anterior-posterior and lateral views)	32	8 (25%)
Ultrasonography	32	18 (56%)
MRI	24	18 (75%)

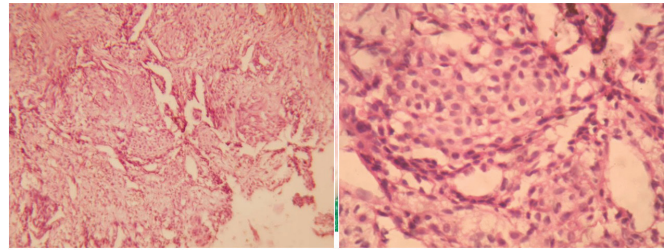


Figure 5: Sheets of glomus cells separated by varying-sized vessels (H&E X100). Glomus cells with pale cytoplasm, well-defined cell margin and round to ovoid pinched-out central nuclei (H&E X 400).

In our series, an MRI was done on 24 lesions. MRI was not ordered for lesions where radiograph showed positive findings. Glomus tumour was detected in 18 (75%) out of 24 digits scanned by MRI. The literature says that about 10% of glomus tumour are missed on MRI.¹⁶

In this study, 6(18.7%) lesions were missed by all the three diagnostic modalities namely plain radiograph, ultrasonography and MRI. Lesions in these cases were very small in size measuring 1.5 to 3 mm. Twenty of the tumours excised by us were between 3 to 5 mm in diameter. Smallest one was about 1.5 mm and largest 12 mm. All lesions were encapsulated and easily removed. Histopathological examination of all lesions proved them to be glomus tumours (Figure 5).

The post-operative course was uneventful in all cases. There was complete relief of symptoms in all cases. No significant postoperative nail deformity was seen in 24 cases. There was no significant preoperative deformity in these nails. Eight cases had split nail deformity preoperatively. In three of these cases nail was further deformed by surgery as nail bed was grossly atrophic.

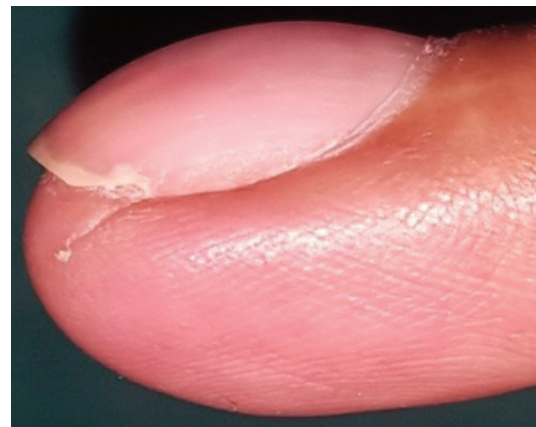


Figure 6: Recurrent subungual glomus tumour. The scar of previous surgery is visible.

The follow-up period of our patients is fairly long ranging from six to ten years. Two patients had a recurrence of tumour in same nail bed. Both were relieved of their symptoms after first surgery and remained asymptomatic for months together. One patient presented with a complaint of pain 10 months after the first surgery. Another with pain and nail deformity after approximately 15 months of the first surgery (Figure 6).

Both were re-operated by the same surgical approach 13 and 18 months after their previous surgery. The histology of the recurrent tumour was similar to the primary tumour in both cases. Residual tumour may be the cause of recurrence.

CONCLUSION

The high degree of suspicion, detailed history and meticulous clinical examination is most important for diagnosing subungual glomus tumour. Plain radiographs, ultrasonography and MRI are well-established modalities for confirmation of diagnosis. All cases should be adequately investigated to confirm the diagnosis before surgery. After confirmation of diagnosis treatment is excision of tumour. But in a significant number of cases (18.7% in our study) these investigations miss glomus tumour. Such patients suffer a lot and are referred from one department to another for months. This diagnostic dilemma should be discussed with the patient and the option of nail bed exploration should be given. If a glomus tumour is detected on exploration, then curative excision is done. This will prevent the unnecessary prolonged suffering of these patients. After proper clinical evaluation chances of negative exploration are minimal.

REFERENCES

1. Wood W. On Painful Subcutaneous Tubercle. *Edinb Med Surg J.* 1812 Jul 1;8(31):283-291. PMID: 30329513; PMCID: PMC5744552.

2. Kolaczek J. Ueber das angio-sarkom. *Deutsche Zeitschrift f. Chirurgie.* (1878)9, 165–227.
3. Masson P. Le glomus neuromyoarterial des regions tactiles et ses tumeurs. *Lyon Chirurgical.* 1924;21:257-280.
4. Rettig AC, Strickland JW. Glomus tumor of the digits. *J Hand Surg Am.* 1977 Jul;2(4):261-5. doi: 10.1016/s0363-5023(77)80121-4. PMID: 197147.
5. Carroll RE, Berman AT. Glomus tumors of the hand. *J Bone Joint Surg.* 1972; 54A:691-703.
6. Graham B, Wolf TW. Synchronous subungual glomus tumors in adjacent digits. *J Hand Surg.* 1992;17B:575-6
7. McEvoy BF, Waldman PM, Tye MJ. Multiple hamartomatous glomus tumors of the skin. *Arch Dermatol.* 1971 Aug;104(2):188-91. PMID: 4328526
8. Van Geertruyden J, Lorea P, Goldschmidt D, de Fontaine S, Schuind F, Kinnen L, Ledoux P, Moermans JP. Glomus tumours of the hand. A retrospective study of 51 cases. *J Hand Surg Br.* 1996 Apr;21(2):257-60. doi: 10.1016/s0266-7681(96)80110-0. PMID: 8732413.
9. Giele H. Hildreth's test is a reliable clinical sign for the diagnosis of glomus tumors. *J Hand Surg.* 2002; 27B:157-158.
10. Ekin A, Özkan M, Kabaklioglu T. Subungual glomus tumors: a different approach to diagnosis and treatment. *J Hand Surg.* 1997;22B:228-229.
11. Bhaskaranand K, Navadgi BC. Glomus tumor of the hand. *J Hand Surg.* 2002;278:229-231
12. Morey VM, Garg B, Kotwal PP. Glomus tumours of the hand: review of literature. *J Clin Orthop Trauma.* 2016;7:286-291.
13. Tada H, Hirayama T, Takemitsu Y. Prevention of postoperative nail deformity after subungual glomus resection. *J Hand Surg Am.* 1994 May;19(3):500-3. doi: 10.1016/0363-5023(94)90070-1. PMID: 8056982.
14. Ogino T, Ohnishi N. Ultrasonography of a Subungual Glomus Tumour. *Journal of Hand Surgery (British and European Volume, 1993);*18B:746-747
15. Matloub HS, Muoneke VN, Prevel CD, Sanger JR, Yousif NJ. Glomus tumor imaging: Use of MRI for localization of occult lesions. *The Journal of Hand Surgery.* 1992; 17(3):472-475. doi:10.1016/0363-5023(92)90353-Q.
16. Al-Quattam MM, Al-Namla A, Al-Thunayan A, Al-Subhi F, El-Shayeb AF. Magnetic Resonance Imaging in diagnosis of glomus tumours of hand. *J. Hand Surgery Br.*2005;30: 535-540