

Frequency and Location of Cutaneous Perforators of Thigh: A Cadaveric Study

Ritu Singh¹,
Navneet Kumar²,
Pooja Singh³,
A.K. Pankaj²,
Anoop Verma⁴

Keywords:

Cutaneous perforators,
Thigh, Superficial femoral
artery, Cutaneous artery

doi: 10.61081/cjprs/3v1i103

ABSTRACT

Cutaneous perforators are essential for the survival of skin flaps in reconstructive surgery, particularly in thigh flaps. These perforators originate from major arteries, such as the lateral circumflex femoral artery and the superficial femoral artery. Understanding the vascular anatomy of these perforators enhances the effectiveness of reconstructive procedures.

A study was conducted on 15 lower limbs to determine the frequency and location of the cutaneous perforators in the thigh after injecting methylene blue dye. A total of 443 perforators were observed in the thigh. The highest number of perforators originated from the superficial femoral artery (25.2%), followed by the perforating femoral artery (21.4%), lateral circumflex femoral artery (23.7%), medial circumflex femoral artery (20.7%), and perforating obturator artery (8.08%).

A thorough understanding of the vascular anatomy of these perforators will benefit reconstructive surgeons when harvesting skin flaps.

Clinical Journal of Plastic and Reconstructive Surgery, 2025;3(1).

INTRODUCTION

Cutaneous perforators are blood vessels that supply skin and subcutaneous tissue by penetrating muscles and fascia. They play a crucial role for the survival of skin flaps used in reconstructive surgery, particularly in the thigh flap. These perforators originate from major arteries like the lateral circumflex femoral artery and Superficial Femoral

Artery. Substantial anatomical investigation in area of skin vasculature increases the knowledge of surgeons regarding the vascular anatomy of the cutaneous perforators that undoubtedly benefit reconstructive areas and plays important role in harvesting perforator flaps.

Aims & objective: To study the frequency and location of cutaneous perforators of thigh.

MATERIAL & METHOD

The study was conducted on 15 lower limbs of adult fresh cadavers of either sex. After cannulation and dissection by standard techniques perforators of lower limb were located in relation to standard bony landmarks and their distance from main source vessels were measured.

OBSERVATIONS AND RESULTS

In a study of 15 lower limbs, a total of 817 perforators were observed. The contributing arteries and their percentages were as follows: SFA (25.2%), PFA (21.4%), LCFA (23.7%), MCFA (20.7%), POA (8.08%).

¹Department of Anatomy, United Institute of Medical Sciences, Prayagraj, UP, India

²Department of Anatomy, King George's Medical University, Lucknow, UP, India

³Department of Anatomy, Shri Shankaracharya Institute of Medical Sciences, Bhilai, Chhattisgarh, India

⁴Department of Forensic Medicine, King George's Medical University, Lucknow, UP, India

*Correspondence: Navneet Kumar (navneetchauhan@hotmail.com)

Conflicts of interest: None declared.

Funding: None declared.

How to cite: Kumar N, Singh R, Singh P, Pankaj AK, Verma AK. Frequency and Location of Cutaneous Perforators of Thigh: A Cadaveric Study. *Clinical Journal of Plastic and Reconstructive Surgery*. 2025;3(1):7-9

The average number of perforators were found as follows:

- Superficial femoral artery: 112, 7.5 ± 1.7 perforators,
- Profunda femoris artery: 95, 6.3 ± 1.0 perforators,
- Lateral circumflex femoral artery: 105, 7.0 ± 1.6 perforators,
- Medial circumflex femoral artery: 92, 3.5 ± 1.1 perforators, mean length of 35 ± 10 mm.
- Popliteal artery: 39, 5.0 ± 0.7 perforators,

Perforators from SFA originated as direct cutaneous branch as branch from descending genicular artery (DGA) and as branch from saphenous artery. An average of 3.4 ± 1.7 perforators were found as direct cutaneous branch from SFA. A consistent direct perforator of SFA was present 15 ± 2 cm. proximal to SMBP.

DISCUSSION

Sananpanich *et al.* 2013,¹ 52% originated from SFA. Gocmen *et al.* (2012),² found from saphenous artery originated from DGA and 1 to 4 perforators. Perforators of superficial femoral artery (SFA) were found to be distributed in two places one being proximal to superomedial border of patella (SMBP) 55.3%), supplied the anteromedial aspect of thigh with an average of 4.1 ± 1.4 number of perforators. Other group of perforators were found proximal and at mean of 3 cm. posterior to SMBP, an average of 3.3 ± 0.4 number found in this region, Gocmen *et al.* (2012),² found Zheng *et al.* 2015,³ showed that constant perforators of osteoarticular branch of DGA distal anteromedial of thigh.

DGA originated at an average distance of 16.6 ± 2.7 cm. proximal and posterior to SMBP in 80% of cases and in all cases it gives two branches, saphenous artery and musculoarticular artery, at a mean distance of 4.5 cm. distal to its origin. Saphenous branch found to have an average of 3 ± 0 perforators located at an average distance of 1.7 ± 1.2 cm., 4.7 ± 1.6 cm. and 7.9 ± 1.9 cm. proximal to and posterior to SMBP. Perforators of musculoarticular branch of the DGA in all cases were located at an average distance of 5.0 ± 1 cm. proximal to SMBP, supplied the skin of distal anteromedial thigh. Mojallal *et al.* (2013),⁴ studied 14 lower limb and

found a constant direct perforator from SFA, below the pubic tubercle

In this current study, we observed perforators of PFA in two rows, one along mid popliteal line and below gluteal fold (48.4%), and other below gluteal fold and at mean of 4.5 cm. lateral to midpopliteal line (51.6%), these perforators supplied the skin of posterior and posterolateral aspect of thigh respectively. Geddes *et al.* 2003,⁵ observed average 7 to 8 perforators from PFA posterior to thigh, 3 to 4 perforators midline inferior to gluteal fold. Mean number of perforators along midpopliteal line was 3.06 ± 0.3 , and that lateral to midpopliteal line was 3.3 ± 1.0 . It was found that proximal most perforators along midpopliteal line were located at an average distance of 4.9 ± 0.7 cm and distal most at an average distance of 11.9 ± 2.5 cm. below gluteal fold having

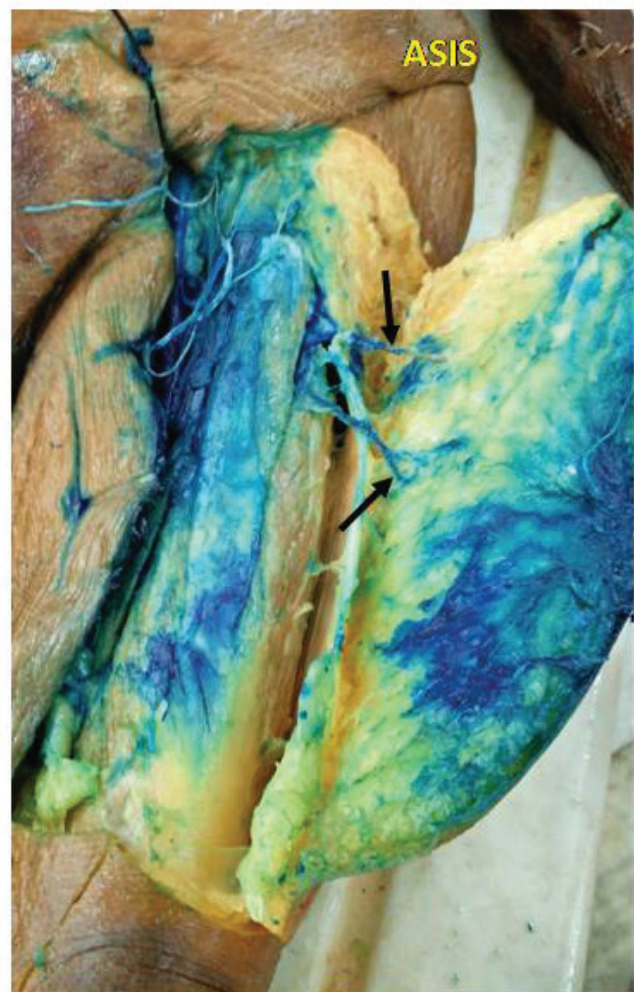

Figure 1: Perforators (black arrow) of LCFA in middle third of left thigh.

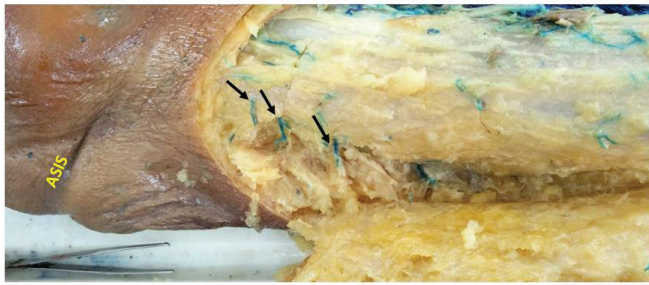


Figure 2: Perforators (black arrow) of LCFA in upper third of right thigh.

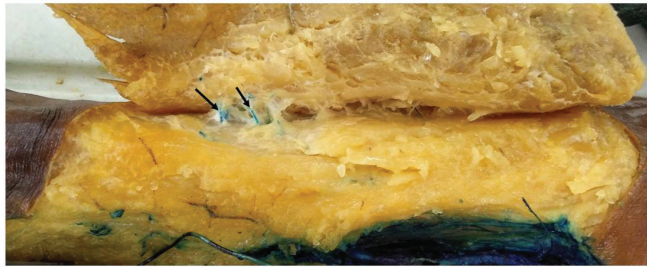


Figure 3: Perforators (black arrow) of LCFA in lower third of right thigh.

mean length of 74 ± 6 mm. (65 – 85) and 67 ± 8 mm. (55 – 80), respectively.

Saad *et al.* (2012),⁶ find below the inferior gluteal fold, Ahmad Zadeh *et al.* (2006),⁷ observed 8 perforator from PFA and 5 ± 2 perforators posterior aspect of thigh then 6 perforator below inferior gluteal line. Perforators of PFA, supplied the skin over posterolateral aspect of thigh, at an average distance of 4.6 ± 0.8 cm. lateral to middle, and were within 4.5 to 18.5 cm. inferior to gluteal fold having mean length of 58 ± 7 mm. (48–70 mm.).

Total of 105 perforators of lateral circumflex femoral artery (LCFA) in 15 lower limb were found, supplied per anterolateral aspect of thigh in between ASIS and superolateral border of patella (SLBP) with an average of 7.0 ± 1.6 perforators. It was observed that maximum number of perforators were located in middle third of thigh (61.68%) (Figure 1) having an average of 4.1 ± 1.2 of perforators followed by upper third of thigh (30.84%) (Figure 2) having an average of 2.3 ± 0.9 , and lower third of thigh (7.48%) (Figure 3) having an average of 0.6 ± 0.7 . An average distance of perforator in the upper third of thigh, middle third of thigh and lower third of thigh was at 29.0 ± 1.6 cm., 19.6 ± 4 cm. and 12.6

± 0.7 cm proximal to SLBP, respectively. Choi *et al.* 2007, found 0 to cutaneous perforators from lateral circumflex artery.⁸

CONCLUSION

The study was an attempt to delineate the perforators of thigh after injecting methylene blue dye. Total Number of Perforators in thigh region were observed 443 and maximum numbers of perforators were arisen from superficial femoral artery. The detailed understanding and knowledge of this vascular anatomy of perforators will benefit reconstructive surgeons in harvesting skin flaps.

REFERENCES

1. Sananpanich K, Atthakomol P, Luevitonvechkij S, Kraissarin J. Anatomical variations of the saphenous and descending genicular artery perforators: cadaveric study and clinical implications for vascular flaps. *Plastic and Reconstructive Surgery*. 2013 Mar 1;131(3):363e-72e.
2. Gocmen-Mas NE, Aksu FU, Edizer M, Magden O, Tayfur V, Seyhan T. The arterial anatomy of the saphenous flap: a cadaveric study. *Folia Morphologica*. 2012;71(1):10-4.
3. Zheng HP, Zhuang YH, Lin J, Zhang YX, Levin LS, Grassetti L, Lazzeri D, Persichetti P. Revisit of the anatomy of the distal perforator of the descending genicular artery and clinical application of its perforator “propeller” flap in the reconstruction of soft tissue defects around the knee. *Microsurgery*. 2015 Jul;35(5):370-9.
4. Mojallal A, Boucher F, Shipkov H, Saint-Cyr M, Braye F. Superficial femoral artery perforator flap: anatomical study of a new flap and clinical cases. *Plastic and Reconstructive Surgery*. 2014 Apr 1;133(4):934-44.
5. Geddes CR, Morris SF, Neligan PC. Perforator flaps: evolution, classification, and applications. *Annals of plastic surgery*. 2003 Jan 1;50(1):90-9.
6. Saad A, Sadeghi A, Allen RJ. The anatomic basis of the profunda femoris artery perforator flap: a new option for autologous breast reconstruction—a cadaveric and computer tomography angiogram study. *Journal of Reconstructive Microsurgery*. 2012 Jul;28(06):381-6.
7. Ahmadzadeh R, Bergeron L, Tang M, Geddes CR, Morris SF. The posterior thigh perforator flap or profunda femoris artery perforator flap. *Plastic and reconstructive surgery*. 2007 Jan 1;119(1):194-200.
8. Choi SW, Park JY, Hur MS, Park HD, Kang HJ, Hu KS, Kim HJ. An anatomic assessment on perforators of the lateral circumflex femoral artery for anterolateral thigh flap. *Journal of craniofacial surgery*. 2007 Jul 1;18(4):866-71.
9. Blondeel PN, Morris SF, Hallock GG, Neligan PC, editors. *Perforator flaps: anatomy, technique, & clinical applications*. CRC press; 2013 Jul 1.