



Ureteric Endometriosis: A Rare but Important Entity

Sonu Singh*, Shruti Gupta

Department of Gynecology, Vivekananda Polyclinic and Institute of Medical Sciences, Lucknow, UP, India

Abstract

Endometriosis is described as the availability of endometrium-like tissue other than its normal position. It affects around 1 in 10 women and may affect women of any age. Out of all, Ureteral endometriosis (UE) is found in only 0.1-1% of women only and many times remains undiagnosed as the patient does not present with specific symptoms. Timely diagnosis and management of UE treatment becomes essential as it may lead to hydronephrosis and even may lead to kidney failure. We are presenting a case report of a woman with severe dysmenorrhoea. Imaging studies and laparoscopy showed left-sided large ovarian endometrioma and deep infiltrating endometriosis (DIE) findings with hydroureter on ultrasound and MRI.

ARTICLE INFO

*Correspondence:

Sonu Singh
rdsonusingh2007@rediffmail.com

Department of Gynecology,
Vivekananda Polyclinic and Institute of Medical Sciences, Lucknow, UP, India

Dates:

Published: 24-07-2023

Keywords:

Endometriosis,
Hydronephrosis,
Laparoscopy, Magnetic resonance imaging,
Ureter

Financial support:

Nil

Conflict of Interest:

The authors have no conflict of interest

How to Cite:

Singh S, Gupta S. Ureteric Endometriosis: A Rare but Important Entity. Journal of Clinical Practice. 2023;17(1):18-20

INTRODUCTION:

Endometriosis is described as the availability of endometrium-like tissue at sites other than the normal uterine cavity. It is a common gynecological disease of females affecting all ages, especially reproductive age. We know that it can involve pelvic as well as extra pelvic organs. Endometriosis of pelvic organs mainly involves the ovary, peritoneum, uterosacral and bowel etc. Out of all, about 10% of women may have genitourinary tract involvement. Bladder endometriosis is more common than ureteral endometriosis (UE). UE is very rare and consists of only 0.3% of all kinds of endometriosis.¹ UE can be extrinsic (more common 80%) or intrinsic (rare).

It mainly occurs associated with the involvement of uterosacral ligaments or the pressure effect of encasing ovarian endometrioma mass. Many times, involvement of the ureter is not diagnosed and the patient may land up in either hydroureter, or hydronephrosis leading to loss of renal function or complete loss of kidney.

Hence preoperative diagnosis is important for planning surgery and saving kidney function.

CASE REPORT

Mrs X. 36-years-old female, P1L1 previous LSCS 4 years back presented with severe dysmenorrhea VAS -10/10 and dyspareunia for the last 3 years and was admitted to the gynecology department. She had no urinary or bowel complaints. On per vagina examination uterus was normal size and there was fullness and tenderness in the left fornix. On rectovaginal examination, there was tenderness and thickness on the left side.

© Journal of Clinical Practice, 2023. **Open Access** This article is licensed under a Creative Commons Attribution-NonCommercial-ShareAlike 4.0 International (CC BY-NC-SA 4.0) License, which allows users to download and share the article for non-commercial purposes, so long as the article is reproduced in the whole without changes, and the original authorship is acknowledged. If you remix, transform, or build upon the material, you must distribute your contributions under the same license as the original. If your intended use is not permitted by statutory regulation or exceeds the permitted use, you will need to obtain permission directly from the copyright holder. To view a copy of this licence, visit <https://creativecommons.org/licenses/by-nc-sa/4.0/>

On Transvaginal sonography, the uterus was found normal size, the right ovary was normal and there was a large left tubo ovarian mass of 7cm x 8 cm in size and also hydroureter on the left side.

MRI report confirmed hydroureter and detected hydronephrosis of the left side, with confirmation of tub ovarian mass.

LAB REPORTS

Hemoglobin was 11 gm%, Serum creatinine was 8 mg/dL, uric acid was 3.6 mg/dL and the rest of all investigations were normal except for a mild increase in CA 125-45.

Renal function tests report was also within normal range, urine culture was sterile.

After due consent, the decision to do laparoscopic excision of the tubo ovarian mass to release the pressure and constriction around the left ureter was taken.

On laparoscopy, dense adhesions were present in Pouch of Douglas (Figure 1). The first step was a dissection of sigmoid adhesions and identifying ureter on the left pelvic brim which was dilated (Figure 2). Retroperitoneum was opened and the whole large tub of ovarian mass was removed after ureterolysis on the left side. Pararectal space was opened to safeguard the rectum on the medial side and the uterosacral nodule was also removed (Figure 3). Some other lesions were also excised and specimens were removed from the abdomen and sent for histopathology. As the ureter appeared functional, the decision to put DJ stent in the left ureter was taken.

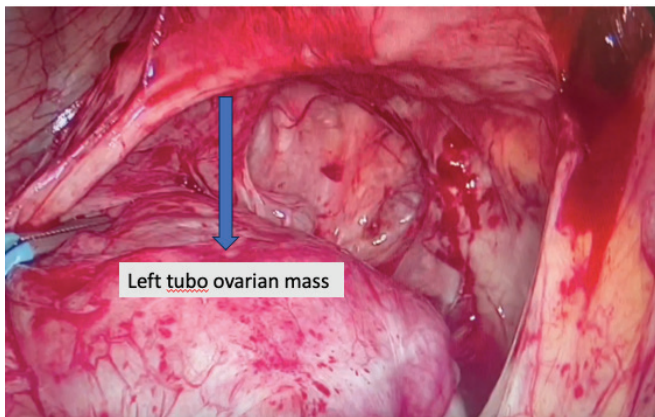


FIG 1: Left large tubo ovarian mass.

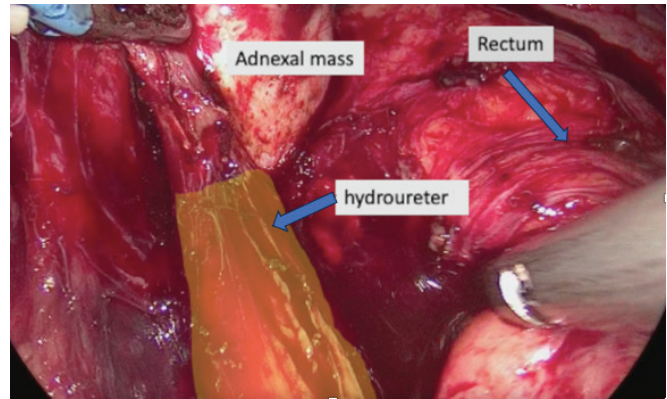


FIG 2: Left hydroureter with dissection of pararectal space..

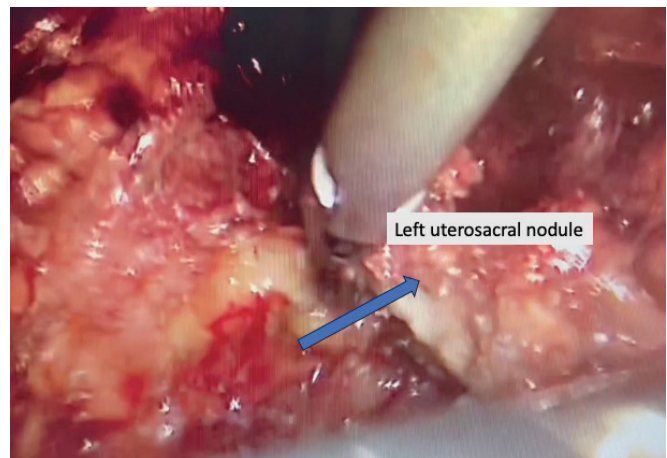


FIG 3: Excision of left uterosacral ligament nodule.

The operative and post-operative period was uneventful and stent removal was done 6 weeks postoperatively. There was a resolution in hydroureter and hydronephrosis. The diagnosis was confirmed on her histopathology report which came to be endometrioma.

DISCUSSION

Urinary tract endometriosis is a very underreported entity. About 80% of cases are of bladder endometriosis followed by ureter, kidneys, and urethra. Ureteric involvement affects around .1 to 1% of women with endometriosis. Patients usually don't have any symptoms related to the urinary tract in the majority of cases. Hence it may affect the function of the kidney due to hydronephrosis and sometimes may lead to total loss of the kidney if remain undiagnosed and treated early.

Imaging in the form of ultrasonography, MRI, CT Urography is diagnostic tool used to confirm involvement of ureter.² Transvaginal ultrasound is the first-line imaging modality for endometriosis and has a high sensitivity for bladder rectovaginal ovarian disease detection.³

MRI is merely accurate for DIE and uterosacral involvement. In patients of suspected UE intravenous urography is done to evaluate other causes of ureteric obstruction.

UE can be extrinsic and intrinsic, with extrinsic being more common. In the extrinsic type, endometrial tissue involves only the outermost layer of ureter but in intrinsic variety, deeper layers are also involved. In the extrinsic type, presentation is mainly in the form of ureteric strictures, ureteral obstruction, and hydronephrosis because of adherence and involvement of surrounding structures like uterosacral ligaments but intrinsic endometriosis occurs by hematogenous or lymphatic spread.

On MRI, the lesion is classified as extrinsic if the contact circumference is less than 180 degrees and intrinsic if the circumference is more than 360 degrees. According to a study MRI appears to be more sensitive (91% versus 82%) but less specific (59% versus 67%) than surgery for the diagnosis of an intrinsic form of ureteric location.⁴ In our case MRI defined extrinsic type of UE and was confirmed by laparoscopy.

Unlike bladder endometriosis, hematuria is not commonly found in UE. Our patient had no hematuria with a left-side large endometrioma and nodule of the uterosacral ligament. The main line of treatment for UE is to relieve the obstruction and protect renal functions. Ureterolysis is the first-choice option for patients with mild

hydronephrosis whereas resection of the ureter with ureteroneocystostomy is suggested for moderate to severe hydronephrosis.⁵ In our case, it was possible to relieve the obstruction without the need for segmental resection and anastomosis.⁶ Due to non-specific symptoms UE is under-diagnosed and usually discovered during laparoscopy. Treatment depends on the stage, location, and depth of involvement of the ureter. Hence it is very important to diagnose UE to prevent renal failure and silent urinary obstruction.⁷

REFERENCES

1. Nezhat C, Nezhat F, Nezhat CH, Nasserbakht F, Rosati M, Seidman DS. Urinary tract endometriosis treated by laparoscopy. *Fertil Steril* 1996; 66:920-4.
2. Mu D, Li X, Zhou G, Guo H. Diagnosis and treatment of ureteral endometriosis: study of 23 cases. *Urol J* 2014; 11:1806-12.
3. Krüger K, Gilly L, Niedobitek-Kreuter G, Mpinou L, Ebert AD. Bladder endometriosis: characterization by magnetic resonance imaging and the value of documenting ureteral involvement. *Eur J Obstet Gynecol Reprod Biol* 2014;176:39-43.
4. Cimsit C, Yoldemir T, Guclu M, Akpınar IN. Susceptibility-weighted magnetic resonance imaging for the evaluation of deep infiltrating endometriosis: preliminary results. *Acta Radiologica*. 2016;57(7):878-885. doi:10.1177/0284185115602147
5. Lusuardi L, Hager M, Sieberer M, et al. Laparoscopic treatment of intrinsic endometriosis of the urinary tract and proposal of a treatment scheme for ureteral endometriosis. *Urology* 2012; 80:1033-8.
6. Hsieh MF, Wu IW, Tsai CJ, Huang SS, Chang LC, Wu MS. Ureteral endometriosis with obstructive uropathy. *Intern Med* 2010; 49:573-6.
7. Rozsnyai F, Roman H, Resch B, et al. Outcomes of surgical management of deep infiltrating endometriosis of the ureter and urinary bladder. *JSLs* 2011; 15:439-47.