Patna Journal of Medicine
An official journal of ***Indian Medical Association, Bihar State Branch***

CASE REPORT

Management of Complex Lower Limb Burn Wound: Our Experience and Challenges

Varun H Kashyap, Veena K. Singh, Jatin Goel, Kuldeep Singh

Department of Burns and Plastic Surgery,All India Institute of Medical Sciences, Patna, Bihar, India

ABSTRACT

Lower limb wounds with significant tissue loss, and exposing bone pose a great challenge in management. Cross-leg flaps were first described in 1854, and are still being used for limb-salvage surgeries, unsuitable for free tissue transfer or in resource-limited settings. Herein we present a case of a 56-year-old woman, with post-traumatic SDH, who sustained deep burn injury to her bilateral foot and leg while sitting near a thermal blower one winter evening, exposing the anterior aspect of her tibia. Limb-salvage surgeries were done including cross-leg 'fascio-cutaneous' flap with a positive outcome. Herein, we share ourexperience showing an impactful and reliable option for limb salvage.

Keywords: Burns, Limb salvage, Lower limb wounds

Patna Journal of Medicine. 98(2): 2024

INTRODUCTION

Burns and their associated injuries are caused by exposure to fire, and hot substances which be very debilitating. Globally around 90% of burn injuries are from low to middle-income countries, areas that lack the crucial healthcare-related infrastructures to decrease the extent and the austerity of burns.[1]

Burns became alarmingly frequent in India in the modern age of industrialization. There are also innumerable instances of accidental burning caused by clothes catching fire on low stoves or open gas rings; the loose flowing end of 'saris' and 'dupatta' of Indian women increases thisdanger enormously. Open fires in winter are an added hazard.[2]

Over 100,000 people are affected by burns in India annually and 20,000 of them die according to rough estimates.[3]

Here we present a case ofa 56-year-old female with grade *i.v.* thermal burn over her right leg with exposed tibia.

Case Presentation

We present a 56-year-old female who was referred to our hospital 1 month after she sustained a burn injury to her both legs and foot while she was sleeping with a thermal blower just in front of her foot one winter night.

The patient had a history of craniotomy for acute SDH, due to which her right lower limb was insensate.The patient sustained a thermal injury for more than 30 minutes, her son came into the site when he smelled a burning char-like substance.

The patient was taken to a local private hospital & found to have a Grade IV burn right leg (Figure 1) where dressing was done & later referred to our hospital.



Figure 1: Grade IV thermal burn right leg with gangrenous great toe.

Corresponding email: *varunhkashyap@gmail.com*

The patient was diagnosed to have a Grade IV thermal burn right leg with exposed Tibia (9cm) & gangrenous great toe with a Grade II thermal burn medial aspect of the left leg.

Daily dressing of the wound was done with 1% acetic acid for a few days until red velvety healthy granulation appeared.

Due to the unavailability of local flap options for exposed tibia at the middle & lower third of the right leg, exposed healthy bone was drilled with 1.5 mm k wire & raw area over the anterior & lateral aspects of the middle & lower third, posterior aspect of middle third of right leg was skin grafted and gangrenous great toe was disarticulated at metatarsophalangeal joint (Figure 2).



Figure 2: POD 8 skin grafting of post thermal burn raw area right foot & leg

2 weeks later, the defect over the right leg with exposed tibia was covered using a conventional fascio-cutaneous cross-leg flap based anteromedially with a 1:3 flap ratio (Figure 5). Split skin grafting was done over the donor site of the flap, harvested from the left thigh.Flap monitoring was done through a window at dressing, around 12 to 16 hours after surgery, venous congestion was noted at distal 30% of the flap for which sutures over the distal caudal aspect of the flap were removed, following which congestion improved.

Plaster of Paris slab dressing with adequate padding over knee and ankle was used to attain proper leg positioning and 10 days later, knee and ankle physiotherapy and mobilization were allowed.

Division and inset of the flap were done after 25 days with serial delay of the flap (Figure 6). 18 to 20 days after flap division, the patient was discharged with painless, wound-free, ambulating bilateral lower limbs.



Figure 3: Good uptake of Split Skin Graft with exposed middle & lower third Tibia.

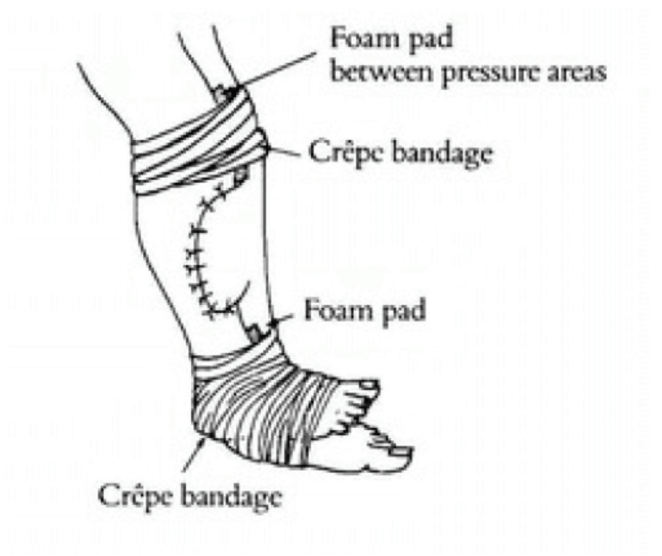

Figure 4: Schematic representation of cross-leg flap.



Figure 5: Anteromedially based cross-leg fascio-cutaneous flap cover



Figure 6: Division &Inset of flap at POD 25

DISCUSSION

Extensive burn injury is amajor problem especially when associated with bone exposures, which eventually lead to drying and sequestration and would necessitate amputation if the bone coverage is not attained as early as possible.

Free flap requires expertise and microvascular reconstruction along with prolonged surgery. Lack of availability of adequate host vessels, and medical instability were the main reason for contraindication for free flap. Cross-leg flaps are a decent way of attaining huge soft tissue defects when advanced reconstructive and microsurgical facilities are not available.[4] In the long term, the cross-leg flap provides good-quality skin with a goodreturn of sensation on a favorable base.[5]

Cross-leg flap plays an important role in coverage and does not require sophisticated surgical expertise and equipment. Efforts to salvage can be rewarding and should be opted where possible.

REFERENCES

1. Peck M, Pressman MA. The correlation between burn mortality rates from fire and flame and the economic status of countries. *Burns*2013; 39:1054–9.
2. Gupta JL. Past, present and future of Plastic Surgery in India - Indian Journal of Plastic Surgery 1991; 24:1-9.
3. Amor A J. World Health, June 1979.
4. VanBoerum MS, Wright T, McFarland M, Fiander M, Pannucci CJ. Cross-leg flaps for lower extremity salvage: a scoping review. *J Reconstr Microsurg.* 2019; 35:505–15.
5. Jayes PH. Cross-leg flaps: a review of sixty cases. *Br J Plast Surg* 1950; 3:1.