

## A CASE REPORT OF CRYPTIC DISSEMINATED TB

Dr U B Singh<sup>1</sup>, Dr Nikhil Prasun<sup>2</sup>

Received:- 15/09/2023

Revised:- 18/09/2023

Accepted:- 20/09/2023

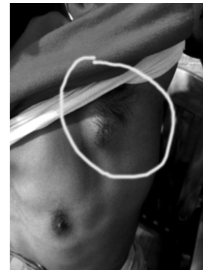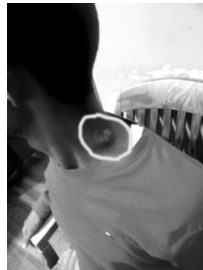**Address for Correspondence:**

1 Consultant Chest Physician, Purnia

2 MD(Med), DM ( Neuro) Consultant Neurologist  
AMRI Hospitals, Salt Lake, Kolkata

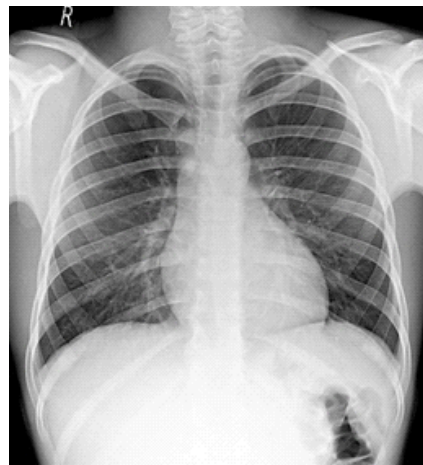
### ABSTRACT

Disseminated TB is a type of TB where mycobacteria spread via blood or lymphatic channels to other organs beyond the lung. It affects two or more non contiguous and non-neighbouring sites of the body. Where as in cryptic disseminated TB lungs are not involved but non contiguous and non neighboring sites are involved. Subject and method. The study is based on the clinical presentations and findings of an outdoor patient who came to my clinic at Purnia. **History Clinical History** A 35 years old male presented with sub acute onset of backache, difficulty in walking and low grade fever for last 2 months. **Personal History** He was a labourer working in Delhi and Punjab. **Past history** Pt was HIV infected and taking ART drugs for last one year. **On Examination** Pt was pale and febrile with run down health, had a rapid wt. loss in last 2 months. Pulse - 100/m, regular , BP 120/80 mm of Hg. There were 2 lymph nodes found at Lt cervical and axillary regions.



Abdomen--- A mass lesion was palpable in right Iliac fossa with marked tenderness. CNS---- It was unremarkable with normal higher functions with no signs of central or peripheral nervous system involvement. No definite signs of paraplegia found. Investigation----

TLC 13100 ,DLC N- 55% L 40%E- 4%,B 1%.,HB 55%CRP 50, FBS, LFT , KFT -WNL HIV positive. Chest X ray ( PA)- Normal



FNAC Of axillary lymph node indicated granulomatous lesion

Access this article online

Website:  
[www.onlinepjm.com](http://www.onlinepjm.com)



Quick Response Code

How to cite this article:

Singh U B , Prasun N, A Case Report Of Cryptic Disseminated Tb

Age / Sex	: 35 years / Male	Pathologist (EX-Sr Resident, IMS, BH)	Patient ID / Billing ID	: 229070 / 246729
Ref. Doctor	: Dr U.B. SINGH MBBS FCIP PGCC	Specimen Collected at	: DIRECT	
Client Name	: DIRECT	Sample Collected On	: 27/11/2023, 03:25 P	
Sample ID	: 23146806	Registration On	: 27/11/2023, 03:23 P	
Printed By	: Mukesh	Reported On	: 28/11/2023, 06:14 P	
		Printed On	: 29/11/2023, 11:02 A	

Test Description	Value(s)	Unit	Bio.Ref. Interval	Method
<b><u>CYTOLOGY</u></b>				
<b><u>FINE NEEDLE ASPIRATION CYTOLOGY (FNAC)*</u></b>				
SPECIMEN:	Axillary lymphnode			
CLINICAL HISTORY:	Not available			
SPECIMEN ADEQUANCY:				
GROSS:	0.1 ml blood mixed aspirate with caseous material			
MICROSCOPIC:	Smears are moderately cellular and show epithelioid granulomas in a back ground of mixed cellular infiltrate comprising of neutrophils, lymphocytes, plasma cells macrophages and occasional giant cells. Caseous necrosis noted.			
IMPRESSION:	FNAC (Axillary lymphnode):- <u>Granulomatous Lymphadenitis</u>			
REVISED:				
<b>**END OF REPORT**</b>				

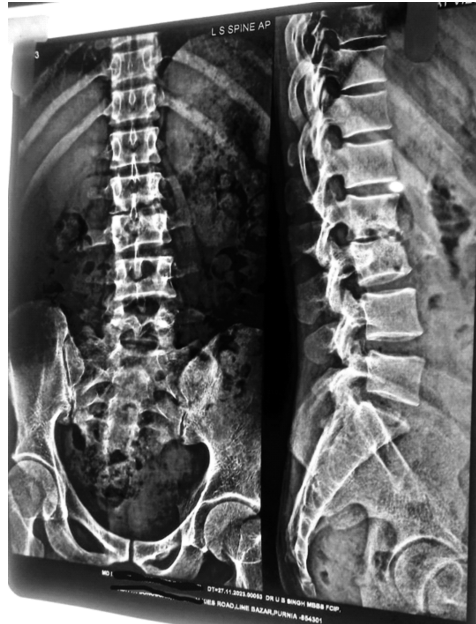**CBNAAT test reports showed**

Age / Sex	: 35 years / Male	Specimen Collected at	: DIRECT
Ref. Doctor	: Dr U.B. SINGH MBBS FCIP PGCC	Sample Collected On	: 27/11/2023, 03:25 P
Client Name	: DIRECT	Registration On	: 27/11/2023, 03:23 P
Sample ID	: 23146807	Reported On	: 28/11/2023, 06:14 P
Printed By	: Mukesh	Printed On	: 29/11/2023, 11:02 A

Investigations	Result(s)
<b><u>MOLECULAR DIAGNOSIS</u></b>	
<b><u>GENXPRT PCR FLUID/SPUTAM/MENSTRUAL BLOOD/FNAC * - I</u></b>	
Specimen	PUS
Mycobacterium tuberculosis complex (REAL TIME PCR ON GENXPRT/ TRUENAT PLATFORM)	<u>DETECTED VERY LOW</u>
Rifampicin Resistance	NOT DETECTED
Isoniazid resistance	
MTB PCR	

MTB detected very low, Rif resistant not detected.



XRAY Of L.S. Spine Report ---

Name	[REDACTED]	Date	27-11-2023
Reff. By	Dr. U. B. Singh (Physician)		
Investigation	X-Ray L.S. spine AP & Lateral view	Patient ID.....	

Destruction of adjacent L2/L3 vertebral bodies end plates are noted with reduced L2/L3 disc space -? Pott's spine.  
 Posterior arch is normal.  
 Pre & para vertebral shadows are normal.  
**Please co-relate with pathoclinical features.**

It shows destruction of L2 L3 vertebral bodies with reduced disc space along with feature of Pott's spine.

PATIENT'S NAME : [REDACTED] 35 YRS / M DATE: 29/08/2023  
 REFERRED BY : DR. MOHADDIS MOMIN SR. NO. : 032908

**M.R.I. OF LUMBO-SACRAL SPINE WITH WHOLE SPINE SCREENING**

TECHNIQUE:- Sag: T1, T2, Cor.: STIR. Ax.: T1, T2.

**FINDINGS:-**

- Mild straightening of lumbar spine is noted.
- Abnormal signal intensity is noted in the L2 & L3 vertebral body with loss of intervening disc space. End plate erosions are noted in the opposing end plates at these levels.
- Minimal abnormal T2 hypointense pre and paravertebral soft tissue is noted at these levels.
- Right psoas abscess is noted measuring 12.0x3.3cm in size. STIR hyperintense signal is noted in the left psoas muscle.
- Thin rim of anterior epidural soft tissue is noted at this level, measuring approximately 3mm in maximum diameter indenting anterior thecal sac.
- Rest of the lumbar vertebrae are normal in height, alignment & marrow signal characteristics.
- Diffuse disc bulge with right foraminal protrusion is noted at L4-L5 level indenting the anterior thecal sac and abutting right exiting nerve root.
- Diffuse disc bulge with right paracentral protrusion and annular tear is noted at L5-S1 level indenting the anterior thecal sac and abutting bilateral traversing & exiting nerve roots.

Lumbar bony canal A.P. diameter at vertebral level measures:				
L1	L2	L3	L4	L5
15.8mm	15.6mm	17.1mm	16.0mm	15.0mm

Lumbar thecal sac A.P. diameter at intervertebral disc level measures:				
L1-L2	L2-L3	L3-L4	L4-L5	L5-S1
13.2mm	12.9mm	11.6mm	13.5mm	10.7mm

- The visualized cord is normal in signal intensity and morphology. Conus is normal in position and signal intensity.
- STIR coronal sections of sacroiliac joints appear unremarkable.
- Incidentally noted are multiple retroperitoneal lymph nodes.
- Screening of cervical spine reveals:- Early degenerative spondylotic changes with marginal end plate osteophytes and desiccated intervertebral discs displaying hypointense signal on T2 weighted images. There are posterior disc bulges noted from C3-C4 to C6-C7 levels indenting the anterior thecal sac, more marked at C5-C6 level.
- Screening of dorsal spine reveals no significant abnormality.

**MRI Of L.S. spine--MRI Findings Supported The X-ray D.L Spine Findings With rt iliopsoas Abscess.  
USG whole abdomen. --**

Name	[REDACTED]		Date	03-10-2023
Ref. By	Dr. U. B. Singh (Physician)			
Investigation	USG scan of whole abdomen	Patient ID.....		

**Liver** is normal in size, shows regular contour & normal parenchymal echogenicity. Intra hepatic Biliary Radicles (IHR) are not dilated. No focal lesion seen.

**Porta Hepatis:** Portal vein & Common Bile Duct are normal in caliber, outline and echotexture.

**Gall Bladder:** Normal in size, distension, outline & wall thickness. No calculus seen.

**Pancreas:** Normal in size and echogenicity. No calcification seen. Pancreatic duct is not dilated.

**Spleen:** Normal in size, shows homogeneous echotexture. No focal lesion seen. Splenoportal axis is patent.

**Right kidney:** is normal in size, shape, position and parenchymal echogenicity. No calculus seen. Pelvicalyceal systems are not dilated. Corticomedullary differentiation is maintained.

**Left kidney:** is normal in size, shape, position and parenchymal echogenicity. No calculus seen. Pelvicalyceal systems are not dilated. Corticomedullary differentiation is maintained.

**Retroperitoneum:** No evidence of sizeable retroperitoneal lymphadenopathy in upper para aortic region. Aorta is normal in caliber and echotexture.

**Urinary bladder:** Normal in distension, outline and wall thickness. No internal echoes seen.

**Prostate:** Normal in size, shows homogeneous echotexture. No median lobe prominence is seen. No calcification or cyst formation is seen within.

**Seminal vesicle:** Both seminal vesicles are unremarkable.

**Impression:** Large loculated ill-defined thick walled hypoechoic collection of 110 x 37 mm size involving right upper iliopsoas muscle. USG findings are suggestive of - Large loculated ill-defined thick walled hypoechoic collection involving right upper iliopsoas muscle - probably iliopsoas abscess (? Cold abscess).

**Suggested:-** Pathoclinical co-relation for further evaluation.

USG findings showed ilio psoas abscess.  
CT finding supported it.

#### **DIAGNOSIS**

So all these positive findings are suggestive of Cryptic Disseminated TB in a HIV Positive patient.

#### **DISCUSSION**

Cryptic disseminated tuberculosis is an insidious form of hematogenously spread tuberculosis, most commonly affecting middle aged and elderly. Cryptic form includes the cases where there is reactivation of a primary complex, as well as those with a small, sometimes undetected chronic focus (1). This can be attributed to impaired cell mediated immunity. HIV infection, CKD, diabetes, immunosuppression, endocrine disorder may alter the typical presentation and atypical presentations are often delayed or even can lead to missed diagnosis of cryptic tuberculosis (2). Mycobacterium tuberculosis isolation from sputum, body fluids or biopsy specimens, histopathological examination of tissue biopsy specimens, and application of molecular methods such as

PCR, can be useful for the confirmation of diagnosis (3). In the modern era of molecular diagnosis, molecular identification of MTB is a must to establish the diagnosis.

#### **CONCLUSION**

The patient was immuno compromised and was suffering from HIV infection having Mycobacterium tuberculosis infection involving more than two non contiguous and non - neighbouring sites of body sparing lungs. Hence it was a case of cryptic disseminated Tuberculosis.

#### **REFERENCE**

- 1 Jacques J, Sloan J. The changing pattern of miliary tuberculosis. Thorax. 1970;25(2):237-40
- 2 Sharma SK, Mohan A. Extra pulmonary tuberculosis. Indian J Med Res. 2004;120:316-53.
- 3 Sharma SK, Mohan A, Sharma A, Mitra DK. Miliary tuberculosis: new insights into an old disease. Lancet Infect Dis. 2005;5:415-30

\*\*\*