

“Dignostic Evaluation Of Secondary Sjogren Syndrome By Lip Biopsy And Serological Markers With Clinical Features – Case Series Of 46 Patient At Tertiary Care Centre Jharkhand”

Dr Deonis Xess

Senior Rheumatologist & Clinical Immunologist, Director Shalby Divine Super speciality Hospital Ranchi

Received:- 12/4/23

Revised:- 17/6/23

Accepted:- 24/7/23

ABSTRACT

Sjögren syndrome is chronic, systemic autoimmune disease characterized by lymphocytic infiltration of the exocrine glands. It is an elaborate involvement of the lacrimal and salivary glands, which eventually lead to keratoconjunctivitis sicca and xerostomia. It may occur in two forms - Primary and secondary, which is associated with another autoimmune disease, most commonly rheumatoid arthritis. Numerous criteria were proposed for diagnosis of Sjögren syndrome. Most widely accepted are American and European group developed international classification criteria for Sjögren syndrome. These criteria include ocular symptoms, oral symptoms, ocular signs, histopathology, salivary gland involvement and sialography. The classification requires four of the six items, one of which must be positive minor salivary gland biopsy or a positive antibody test. Early diagnosis is important to prevent further complications. The aim of this paper is to emphasis on oral changes, advanced diagnosis, and management of Sjögren's syndrome.

Address for Correspondence:

Dr Deonis Xess,
Senior Rheumatologist & Clinical Immunologist
Director Shalby Divine Super speciality Hospital
Ranchi

Introduction

Sjogren's syndrome is a chronic disease characterized by dry mouth and dry eye resulting from immunologically mediated [1] destruction of lacrimal gland and salivary gland . Sjogren's syndrome is an autoimmune epithelitis affecting primarily the exocrine glands and epithelium, characterized by dry mouth and dry eyes. Sjogren's syndrome can be alone (Primary SS) or in association with another autoimmune disease like rheumatoid arthritis(RA) or systemic lupus erythematosus (SLE)when it is called secondary SS.

Prevalence varies from [2] 0.5 to 5% . New American College of Rheumatology classification criteria for sjogren's syndrome have at least two of the following three objective feature. 1. Postive serum anti-SSA/Ro and anti-SSB/La or a positive rheumatoid factor and ANA titer $\geq 1:320$ 2. Minor salivary gland biopsy exhibiting focal lymphocytic 2 sialadenitis with a focus score ≥ 1 focus /4mm 3. Keratoconjunctivitis sicca with ocular staining score ≥ 3 . Minor salivary gland biopsy (sensitivity 64% to 86 %, specificity 90 % to 92 %) is the gold standard diagnosis of [3]. sjogren's syndrome The lesion in

Sjogren's syndrome is termed “focal lymphocytic sialoadenitis” and is characterized by one or more tightly aggregated lymphocytes (more than 50) adjacent to normal gland tissue and surrounding a duct in a 4 square mm area of gland tissue. These aggregates of lymphocytes are called foci and their total density is called a “focus score”. 2 Grade is given by Lymphocytes and plasma cells per 4mm of gland tissue 0 = Absent 1 = Slight infiltrate 2 = Moderate infiltrate or less than 50 lymphocytes/4mm 3 = One focus per 4mm 4 = More than one focus per 4 mm . (Waterhouse and Doniach rst de ned a 'focus' as a cluster of 50 or more lymphocytes, infiltrating the minor salivary glands [5] in case of Sjogren's syndrome in the year 1966.

MATERIAL AND METHOD

INCLUSION CRITERIA –

Patients suffering with sjogren syndrome and who are willing to participate in my study like : - Dry mouth/ Dental caries / Dry eye(Sicca syndrome) - Arthralgia/Arthritis like known cases of other connective tissue disorders e.g. rheumatoid arthritis, SLE, Polymyositis, vasculitis, mixed connective tissue disorder etc.

Access this article online

Website:

www.onlinepjm.com



Quick Response Code

How to cite this article:

Xess D, “Dignostic Evaluation Of Secondary Sjogren Syndrome By Lip Biopsy And Serological Markers With Clinical Features – Case Series Of 46 Patient At Tertiary Care Centre Jharkhand”

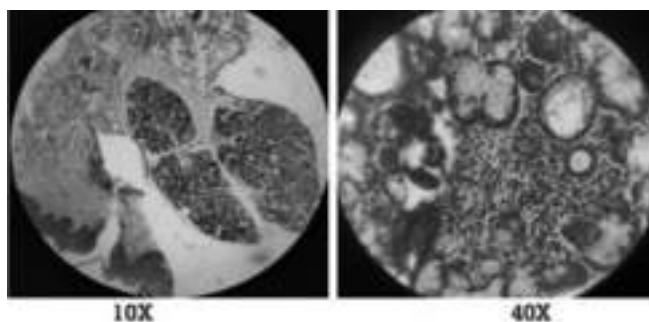
EXCLUSION CRITERIA –

Patient who are not willing to participate
 Seriously ill patient who are unable to comprehend my questionnaire. Patient of sjogren's syndrome other than my inclusion criteria like Post head and neck radiation Serology positive for HCV,HIV etc
 Pre-existing lymphoma Use of drugs like anti-cholinergic, anti-depressant/antipsychotics etc.

STUDY TOOLS –

Consent form Collected minor salivary gland biopsies from relevant patients Various relevant tools for subsequent grossing, tissue processing, blocking, section cutting, staining, mounting. Microscope for slide examination ELISA machine for estimation of serum anti-SSA/Ro, antiSSB/La & ANA

OBSERVATION AND RESULTS PRESENTING FEATURES



SYMPTOMS	No. of Patients
Dry mouth, Arthritis	17
Dental Caries, Arthritis	05
Dry Mouth, Arthritis, Parotid Swelling,	02
Dry Mouth, Dental Caries, Arthritis]	14
Dry Mouth, Dry Eye, Arthritis	05
Dry Mouth, Dry eye, Dental Caries, Arthritis	03

FOCUS SCORE STATUS OF THE PATIENTS (TABLE 2)

FOCUS SCORE	NO. OF PATIENTS
0	01
1	02
2	20
3	22
4	21

SEROLOGICAL PROFILE OF THE PATIENTS (TABLE 3)

ANTIBODIES	NO. OF POSITIVE PATIENTS	NO. OF NEGATIVE PATIENTS
Anti-SSA	44	02

Anti-SSB	32	14
Anti - SSA and Anti - SSB	32	02
ANA	44	02

DISCUSSION

Sjögren's syndrome is an Autoimmune Exocrinopathy involving lacrimal and salivary glands leading to progressive destruction of glands resulting in dry eyes and dry mouths (Cardinal symptoms of the disease), it may exist alone (primary SS) or in Association with other Connective tissue disease(secondary sjogren's syndrome) primary SS [2] constitutes only 0.5% to 5% , secondary sjogren syndrome [6] occurring in 5.5% of northern india patients with RA . and is an uncommon and under diagnosed entity due to lack of awareness amongst treating physicians, ophthalmologist and dentist and even gynaecologist . This report highlights the rarity of this disease in our geographic region. Sjogren's Syndrome typically affects female between age 30- [7] 50 years(M/F =1:9) In Our study 46 patients are of secondary sjogren's Syndrome have sicca symptoms ,dental caries with various other rheumatological disease, mostly Rheumatoid Arthritis(RA) and lesser extend Systemic Lupus Erythematosus (SLE) and mixed connective tissue disorder and among them 2 patients presented with arthritis , parotid swelling and lacrimal gland swelling. Histopathology of lip biopsy of 46 patients , most of them having focus score of 2-3. Two patients were presented with Sicca Syndrome (Xerostomia & Xerophthalmia) , parotid swelling and lacrimal gland swelling who tested negative for RF , Anticcp & Anti-SSA(Ro) , AntiSSB(La),ANA and having low focus score on lip biopsy. All 46 patients were advised for Anti-SSA , Anti-SSB and ANA among them 44 were positive for Anti-SSA & 32 were positive for Anti-SSB. 32 patients are positive for both Anti-SSA & AntiSS B. 2 patients were negative for both Anti-SSA ,Anti-SS B & ANA who have arthritis , dry mouth, parotid swelling and lacrimal gland swelling.

TREATMENT AND OUTCOME

All the patients were managed with the standard of care (Methotrexate , Hydroxychloroquine , Salfasalazine) and secretagogues (Pilocarpine) for dry symptoms who have of Sjogren's Syndrome and Rheumatoid arthritis. Patients with Systemic Lupus

Erythematosus (SLE) and mixed connective tissue disease (MCTD) with Sjogren's Syndrome were treated with hydroxychloroquine and azathioprine along with secretagogues Pilocarpine for dry symptoms. Interesting finding of our study showed, patients have much placebo effect after lip biopsy in respect to sicca syndroms and those patients who were not responded to Sicca Syndrome inspite standard of care were responded when [7] Azathioprine added.

CONCLUSION

Thus, in conclusion Sjogren's Syndrome is an uncommon and underdiagnosed entity in India. Sjogren's Syndrome either primary or secondary diagnosed on the basis of San Francisco Classification criteria which necessarily include serological (Anti-SSA & Anti-SSB) and or lip biopsy. But in resource limited country like India where serological test are not readily available in most part of the country and costly too, lip biopsy will be the cheaper mode of investigation to diagnose Sjogren's Syndrome which also guide for best the

treatment plan.

REFERENCES

1. Kumar, Abbas, Aster. Robbins and Cotran Pathologic basis of disease: Autoimmune disease. South Asia ed. New Delhi: Elsevier; 2017: 226-228.
2. Ved Chaturvedi et al. Manual of Rheumatology: Sjogren's Syndrome. 5 ed.
3. Al Hashimi et al. Xerostomia secondary to Sjögren's syndrome in the elderly: recognition and management. 2005;22(11):887-99 Drugs Aging.
4. D. M. Chisholm and D. K. Mason – Labial salivary gland biopsy in Sjogren's syndrome; J. Clin. Path. [1968], 21, 656-660.
5. Claudio Vitali et al. Sjögren's Syndrome Disease Damage Index and Disease Activity Index .Arthritis & rheumatism. Vol. 56, No. 7, July 2007,
6. International journal of rheumatic disease, 20(7):DOI:10.1111/1756- 185X. 13017
7. The Journal of Rheumatology ,1998;25(5);896-899.
8. VOLUME - 10, ISSUE - 06, JUNE- 2021 • PRINT ISSN No. 2277 - 8160 • DOI : 10.36106/gjra