CASE REPORT VOLUME 4; ISSUE 1 (2026)

Beyond the Dura: Primary Intraosseous Meningioma

Devendra Kulkarni, Poonam Dabhade, Kalpana Vyavhare

Abstract

Intraosseous meningiomas are classified as a subtype of extradural meningiomas. These tumors are found to originate within bone, and a presentation and radiographic appearance different from those of classic extra-axial meningiomas are demonstrated by them. These tumors have also been referred to as primary intraosseous meningiomas. We report a case of 45-year-old female who presented with a scalp swelling in the left parietal region along with headache and seizures since 4 months. MRI confirmed an intraosseous meningioma with both extra-calvarial as well as intracranial extradural extension. The skull radiograph was extremely contributory as a first line of investigation. This report discusses the approach to the diagnosis of the intraosseous meningiomas.

Keywords: Intraosseus, Meningioma.

Journal of Research in Medical and Interpathy Sciences. 4(1);2026; doi: 10.61081/jremedis/4v1i105

Introduction

Meningiomas are derived from arachnoid cap cells of the arachnoid cap villi. Primary extradural meningiomas are considered rare lesions, accounting for less than 2% of all meningiomas. Intraosseous meningiomas are regarded as exceedingly rare lesions and are observed in approximately, 14% of cases of ectopic or primary extradural meningiomas. Most intraosseous meningiomas are composed of osteoblastic or mixed osteoblastic-osteolytic lesions, whereas purely lytic lesions are encountered least commonly. We report the case of 45-year-old female who presented with a scalp swelling in the left parietal region along with headache and seizures since 4 months. Plain radiograph of skull revealed a lytic destructive lesion of the calvarium with sunray type of periosteal reaction.

MRI revealed an expansile intraosseous calvarial lesion with extra-calvarial and intracranial extradural extension, primary diagnosis of intraosseous meningioma was given which was confirmed by FNAC. The pateint underwent Craniotomy with removal of the lesion.

Case Report

A progressively enlarging painless mass over the left frontal region, present for 2-year, was noted in a 45-year-old right-handed woman at presentation. On physical examination, a left frontotemporal bony protuberance was identified, with no associated neurological deficits or other significant findings being observed. Plain radiograph of the skull revealed a predominantly lytic lesion in the left frontoparietal region. The lesion showed a sunray type of periosteal reaction. Noncontrast CT of the head was performed which revealed a lytic destructive lesion involving both the tables of the skull with a large intracranial extra axial soft tissue component associated with it. The lesion was further characterized by using pre- and postcontrast MR imaging. MRI revealed well-defined lytic expansile lesion in the calvarium in the left parietal region. There was an intracranial extra-axial extension of the lesion in the left parietal region in the parasagittal location along with extension in the sub-galeal layers of the scalp. The radiologic preoperative diagnosis was likely an intraosseous lytic meningioma. MR spectroscopy in the intracranial extra-axial component revealed a prominent Choline peak and a raised Choline/Creatinine ratio. The radiologic preoperative diagnosis was likely an intraosseous lytic meningioma. FNAC gave a diagnosis of meningioma. The patient was operated and resection of the mass was done. On pathological examination, a hypercellular meningothelial neoplasm was identified, composed of small cells exhibiting a high nuclear-to-cytoplasmic ratio.

Discussion

Extracranial meningiomas are rare, with a reported incidence of 1–2% of all meningiomas. Numerous variations in the nomenclature of meningiomas of extradural origin have been described. These lesions have been referred to as ectopic, extradural, calvarial, cutaneous, extra-neuraxial, or intraosseous meningiomas. To avoid the use of multiple nomenclatures and the resulting confusion, the umbrella term "primary extradural meningioma" (PEM) was proposed for such lesions. Bone remodelling and calvarial thickening are

1 Department of Radiodiagnosis, SMBT Medical College and Hospital & Research Centre, Nashik, Maharashtra, India

Corresponding Author: Devendra Kulkarni (**Email:** devendrakulkarni2485@gmail.com)

Conflict of Interest: None

Source of Funding: None

How to cite: Kulkarni D, Dabhade P, Vyavhare K. Beyond the Dura: Primary Intraosseous Meningioma. Journal of Research in Medical and Interpathy Sciences. 2026;4(1):17–19

© The Author(s). 2026 Open Access This article is distributed under the terms of the Creative Commons Attribution-NonCommercial-ShareAlike 4.0 International (CC BY-NC-SA 4.0) (https://creativecommons.org/licenses/by-nc-sa/4.0/)

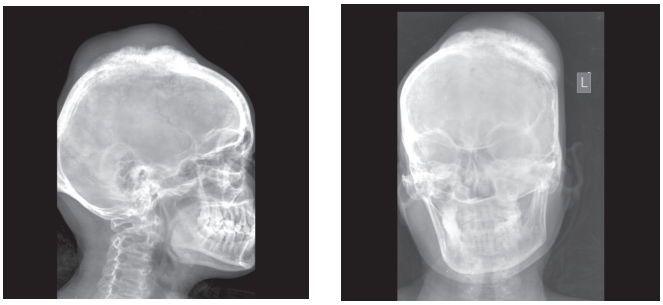

Figure 1: Skull radiograph showing lytic destruction of the calvarium with a sunray-type periosteal reaction and extra-calvarial soft tissue shadow.

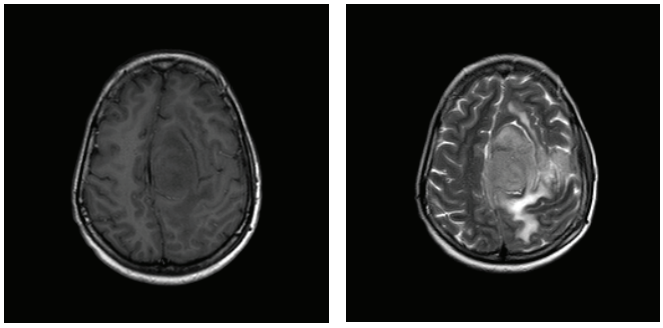

a) b)

Figures 2: a) and b) Pre-contrast T1- and T2-weighted axial MRI images demonstrating the intra-calvarial extra-axial component.

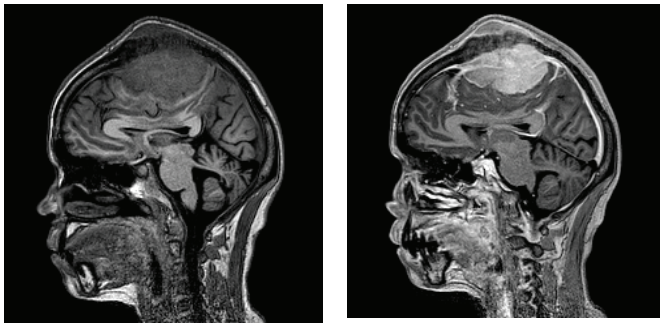

c) d)

Figure 2: c) and d) T1 TSE sagittal pre- and post-contrast MRI images showing a moderately heterogeneous enhancing intraosseous lesion with a large, well-defined, intensely enhancing intra-calvarial extra-axial component.

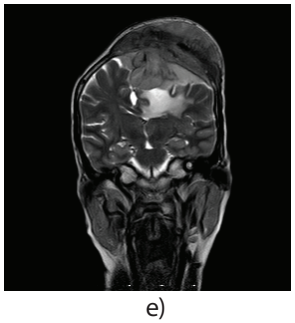

e)

Figure 2: e) T2-weighted coronal MRI image showing the intraosseous lesion with a large, well-defined intra-calvarial extra-axial component.

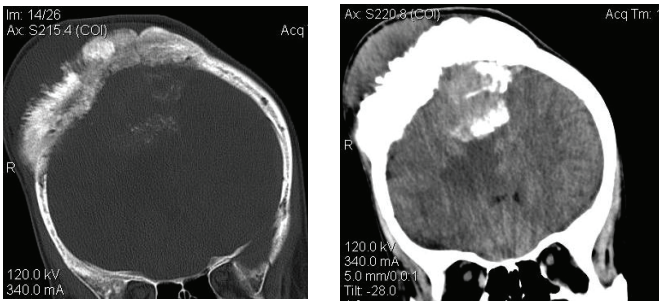

a) b)

Figures 3: a) and b) CT images showing lytic destruction of the calvarium with a sunray-type periosteal reaction and extra-calvarial soft tissue shadow.

frequently observed in these tumours. Further classification has been made into purely extradural (Type I), purely calvarial (Type II), and calvarial with extradural extension (Type III) lesions. Subdivision into convexity (C) or skull base (B) forms is based on the anatomical location. Calvarial thickening at the site of origin of the meningioma is commonly observed. The calvarium is invaded by meningothelial cells, resulting in expansion of the bone. However, diffuse and widespread calvarial thickening is rarely encountered.

Several hypotheses have been proposed regarding the origin of primary extradural and calvarial meningiomas. According to one theory, these lesions are derived from ectopic meningocytes or arachnoid cap cells that become trapped within cranial sutures during moulding of the head at birth. Another hypothesis suggests that they originate from the misplacement and entrapment of meningothelial cells within suture or fracture lines following trauma. Involvement of multiple sutures has also been reported. However, an association with cranial sutures has been identified in only 8% of calvarial meningiomas. Cutaneous meningiomas may be congenital in origin and may arise from arachnoid cell rests located within the skin as a consequence of defective neural tube closure, wherein meningeal tissue becomes separated and incorporated into the surface tissues. This hypothesis may be applicable to the present case, as diffuse

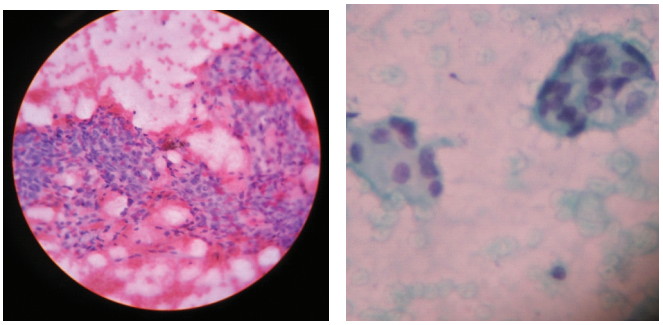

a) b)

Figures 4: a) and b) FNAC photomicrographs showing abundant cellularity with loose clusters and tight whorls of ovoid cells exhibiting bland granular chromatin, pseudonucleoli, and psammoma bodies .

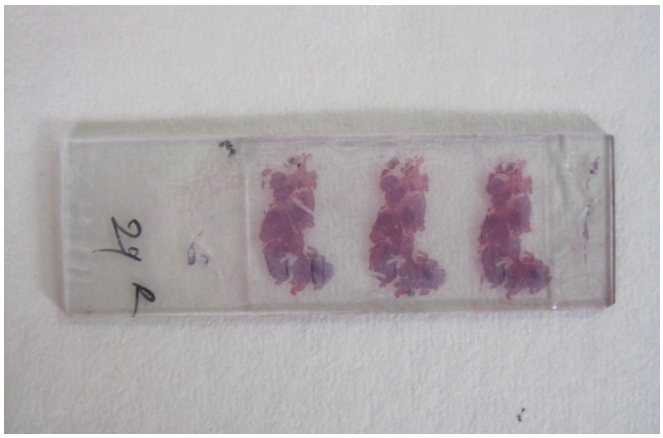

Figures 5: Postoperative histopathological image confirming the diagnosis of primary intraosseous meningioma..

involvement of the frontoparietal bone with extension into the overlying soft tissue was observed. Biologically, calvarial meningiomas are generally slow-growing and benign; however, a greater propensity for malignant transformation has been reported compared with intracranial meningiomas. Lesions presenting with scalp swelling, osteolytic skull defects, and extracranial soft tissue masses are generally considered to be more aggressive. Computed tomography (CT) and magnetic resonance imaging (MRI) are useful for evaluation of the full extent of the lesion, including extradural and calvarial involvement. The differential diagnosis includes plasmacytoma, chondroma, chondrosarcoma, haemangioma, myeloma, eosinophilic granuloma, aneurysmal bone cyst, metastatic disease, and fibrous dysplasia.

Surgical resection is considered the treatment of choice. In cases of diffuse calvarial involvement, wide surgical excision is recommended whenever feasible, followed by cranial reconstruction. Radiotherapy is generally recommended only in cases demonstrating rapid disease progression. When subtotal resection is necessitated by extensive tumour spread or involvement of structures such as the dura, orbit, or paranasal sinuses, regular follow-up with appropriate imaging studies is advised. Excessive intraoperative blood loss may be encountered, and massive blood transfusion may be required. Fatal postoperative coagulopathy secondary to excessive blood loss during surgery has been recognized as a significant complication.

References

1. Azar-Kia B, Sarwar M, Marc JA, Schechter MM. Intraosseous meningioma. Neuroradiology 1974;6:246-253.
2. Turner OA, Laird AT. Meningioma with traumatic etiology. J Neurosurg 1996;24:96-98.
3. Lee HY, Prager J, Hahn Y, Ramsey RG. Intraosseous meningioma. CT and MR appearance. J Comput Assist Tomogr 1992;16:1000-1001.
4. Lopez DA, Silvers DN, Helwig EB. Cutaneous meningiomas-a clinicopathologic study. Cancer1974;34:728-744.
5. Shuangshoti S, Netsky MG, Fitz-Hugh GS. Parapharyngeal meningioma with special reference to cell of origin. Ann Otol Rhinol Laryngol1971; 80;464-73.